

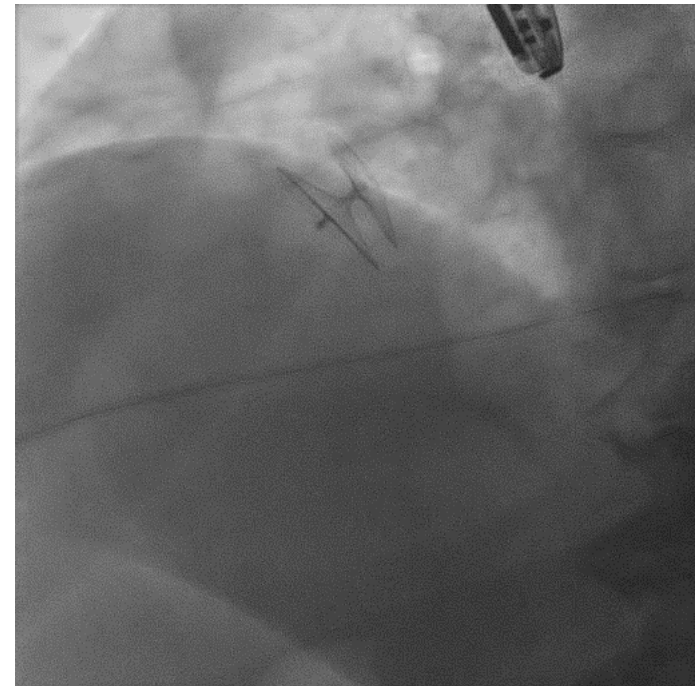
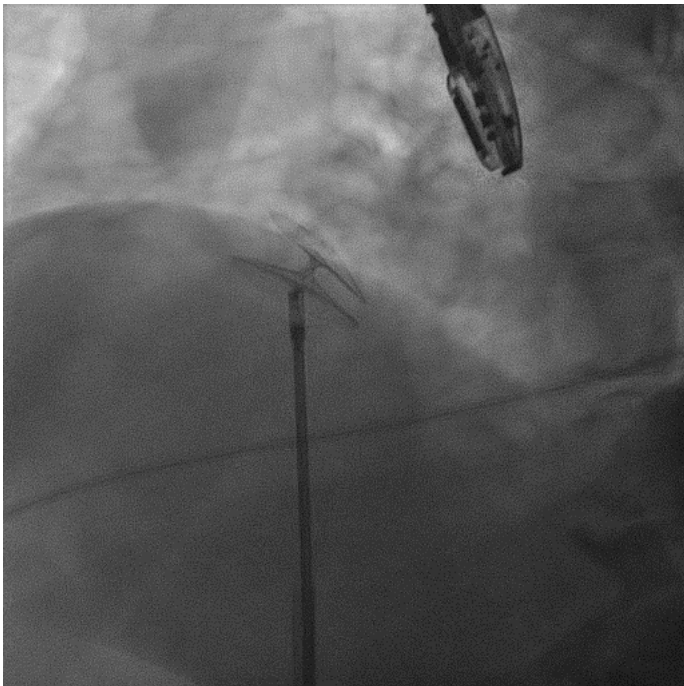


ACTION Study Group
Institute of Cardiology
Pitié-Salpêtrière Hospital
Paris - France

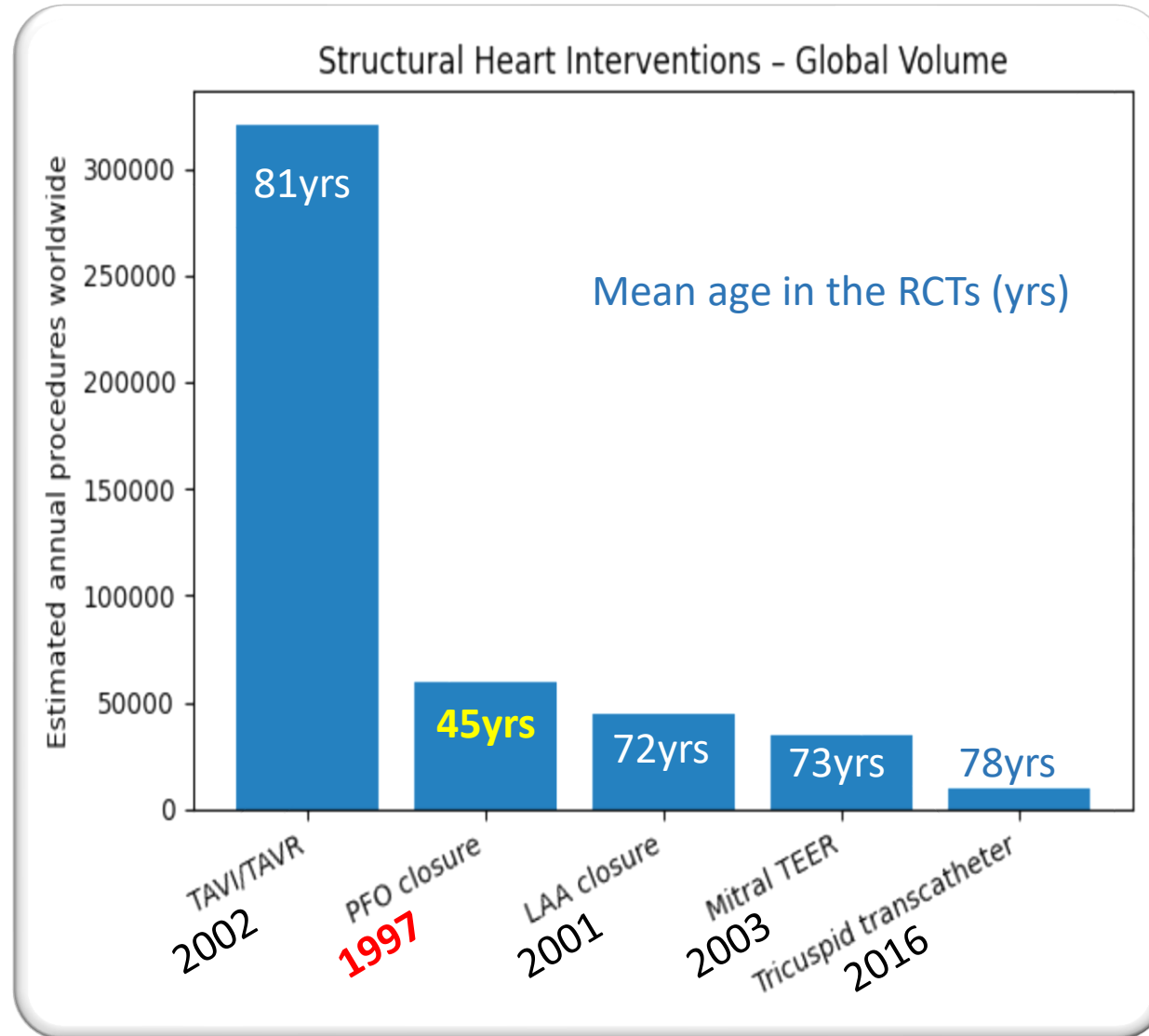


Fermeture percutanée du Foramen Ovale

G. Montalescot

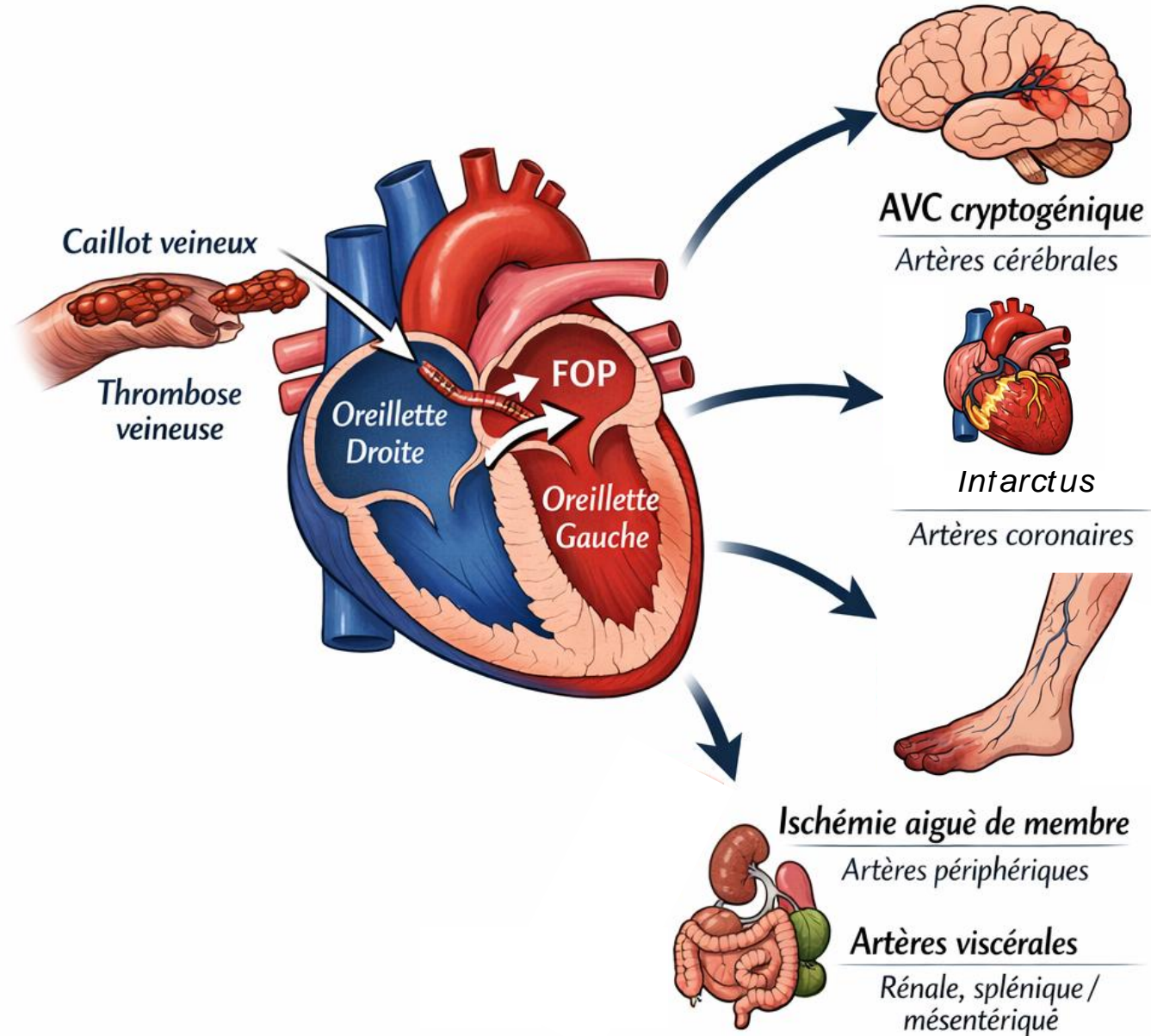


PFO closure second most frequent structural heart procedure



Embolie paradoxale via FOP

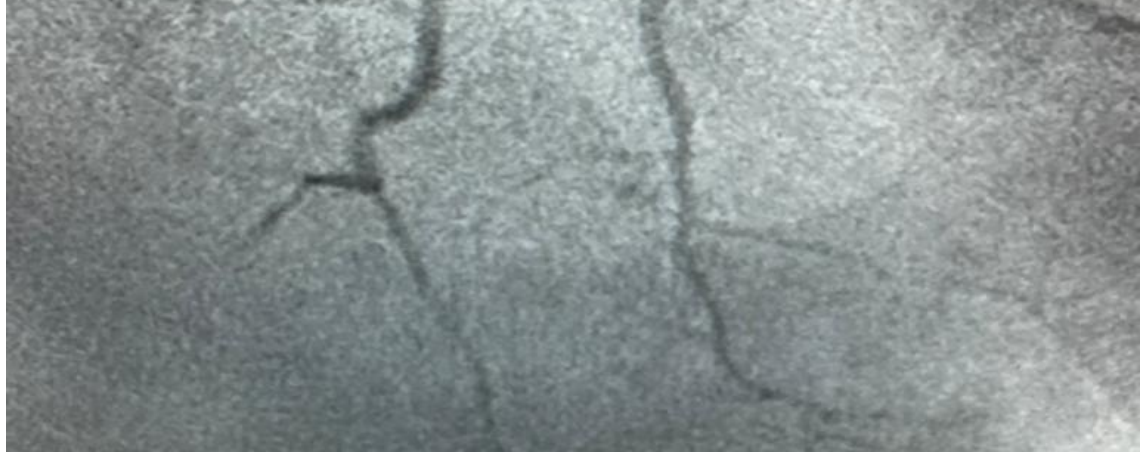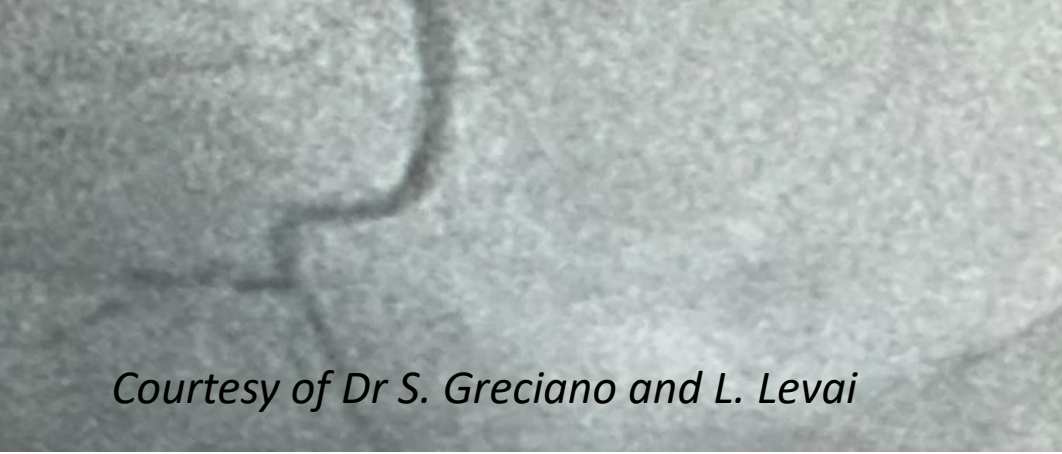
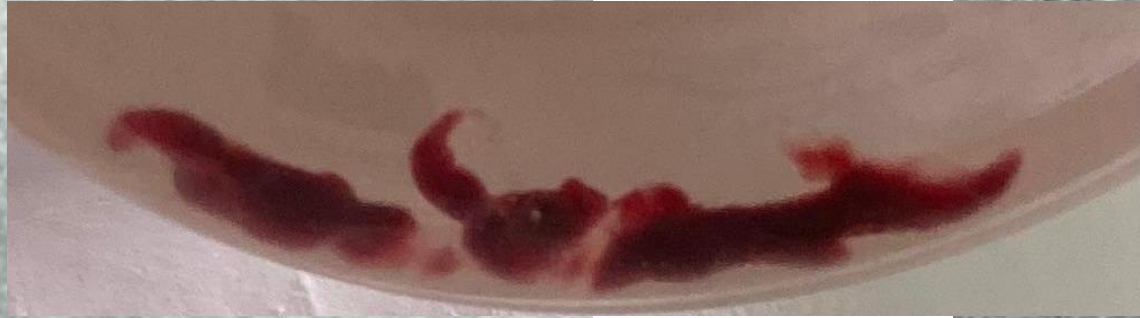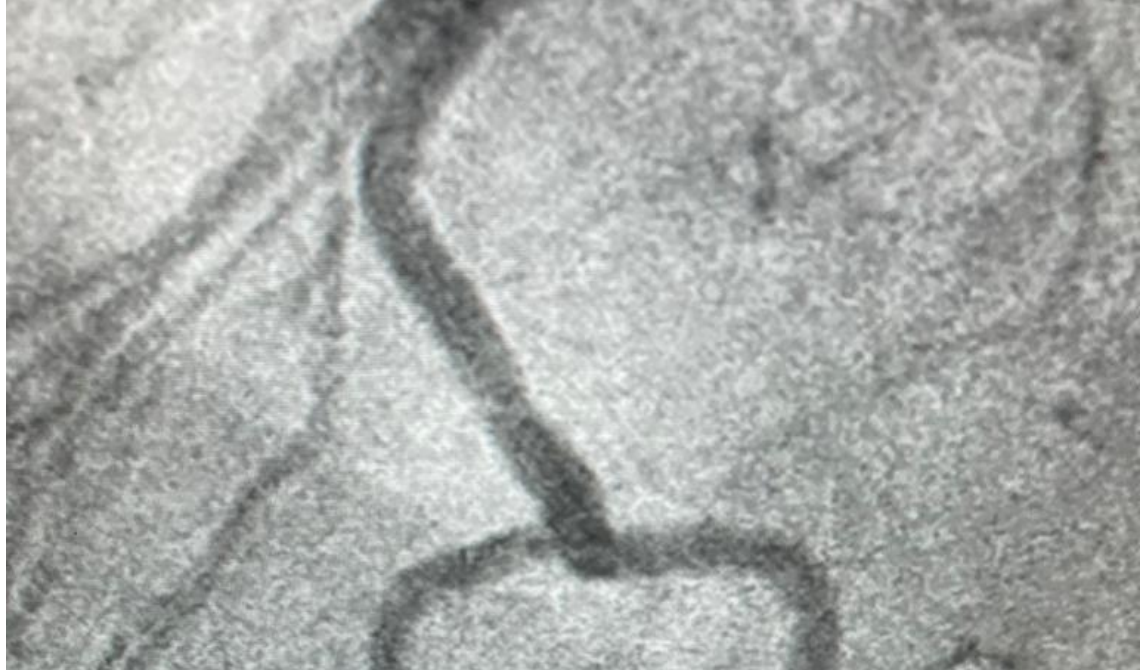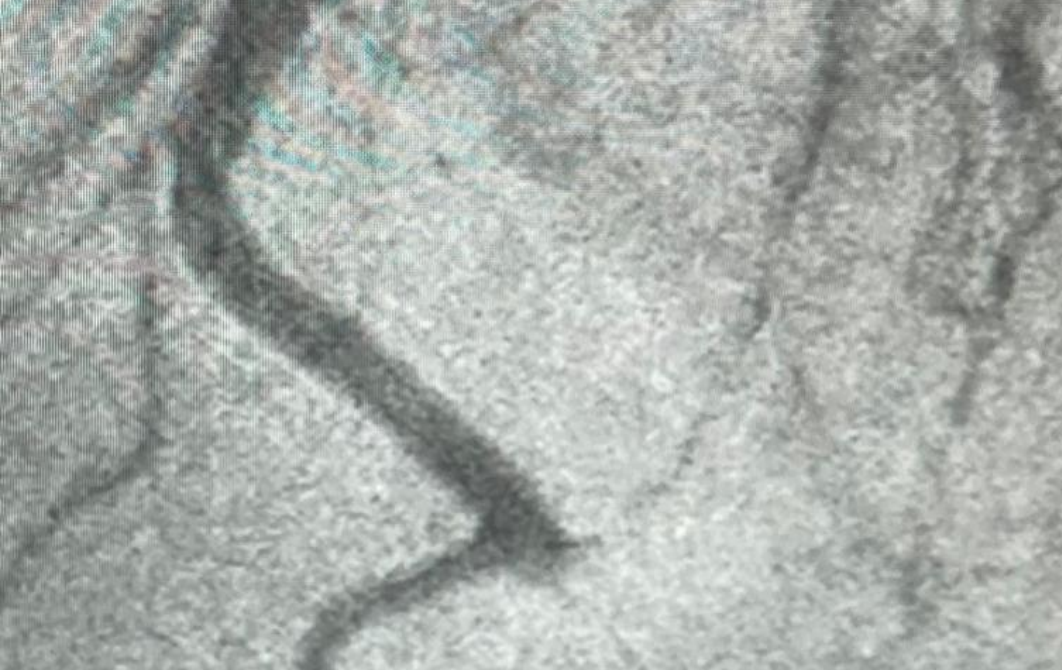Foramen Ovale Perméable \approx 25% de la population



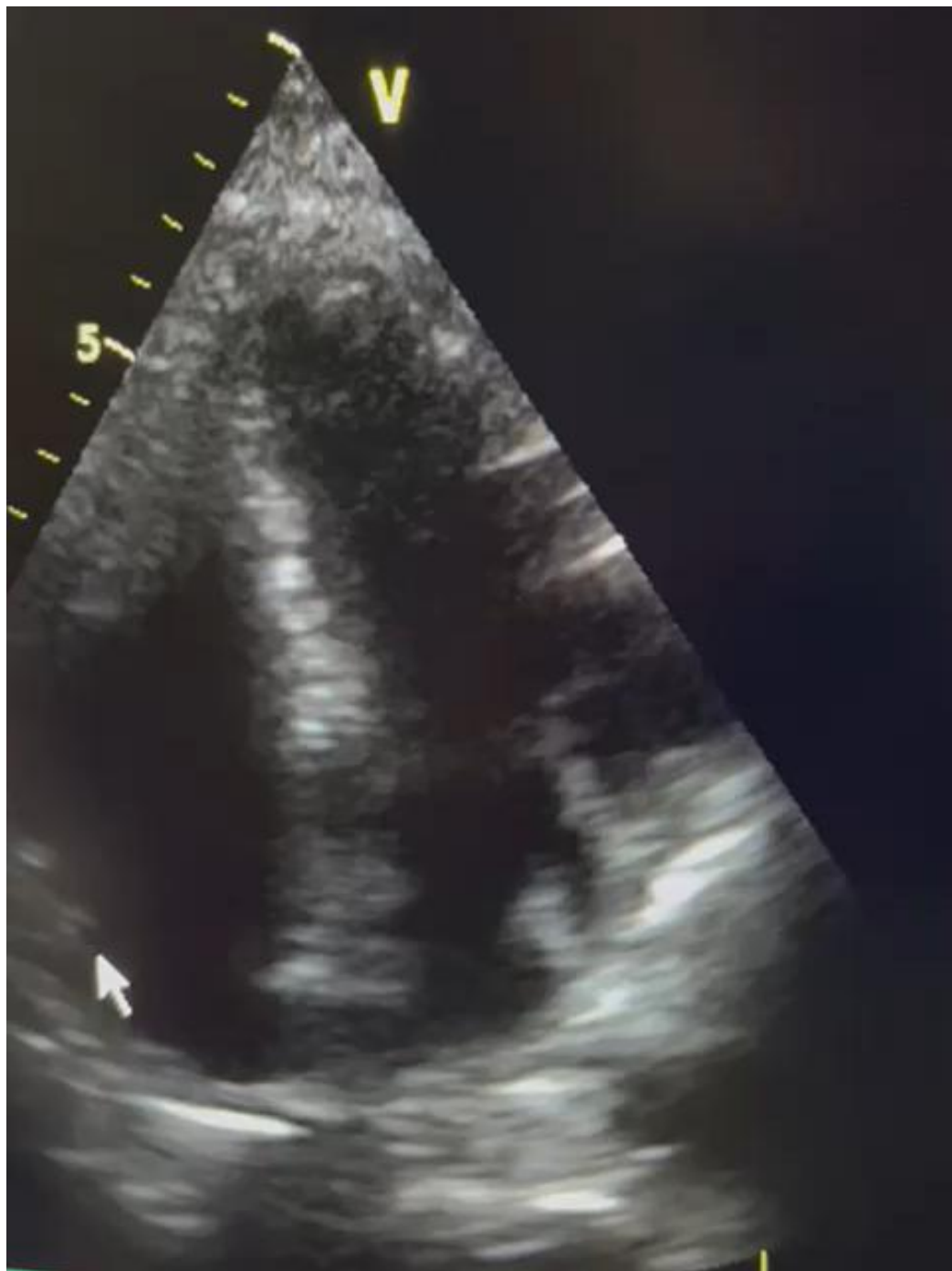
L'embolie paradoxale existe-t-elle?

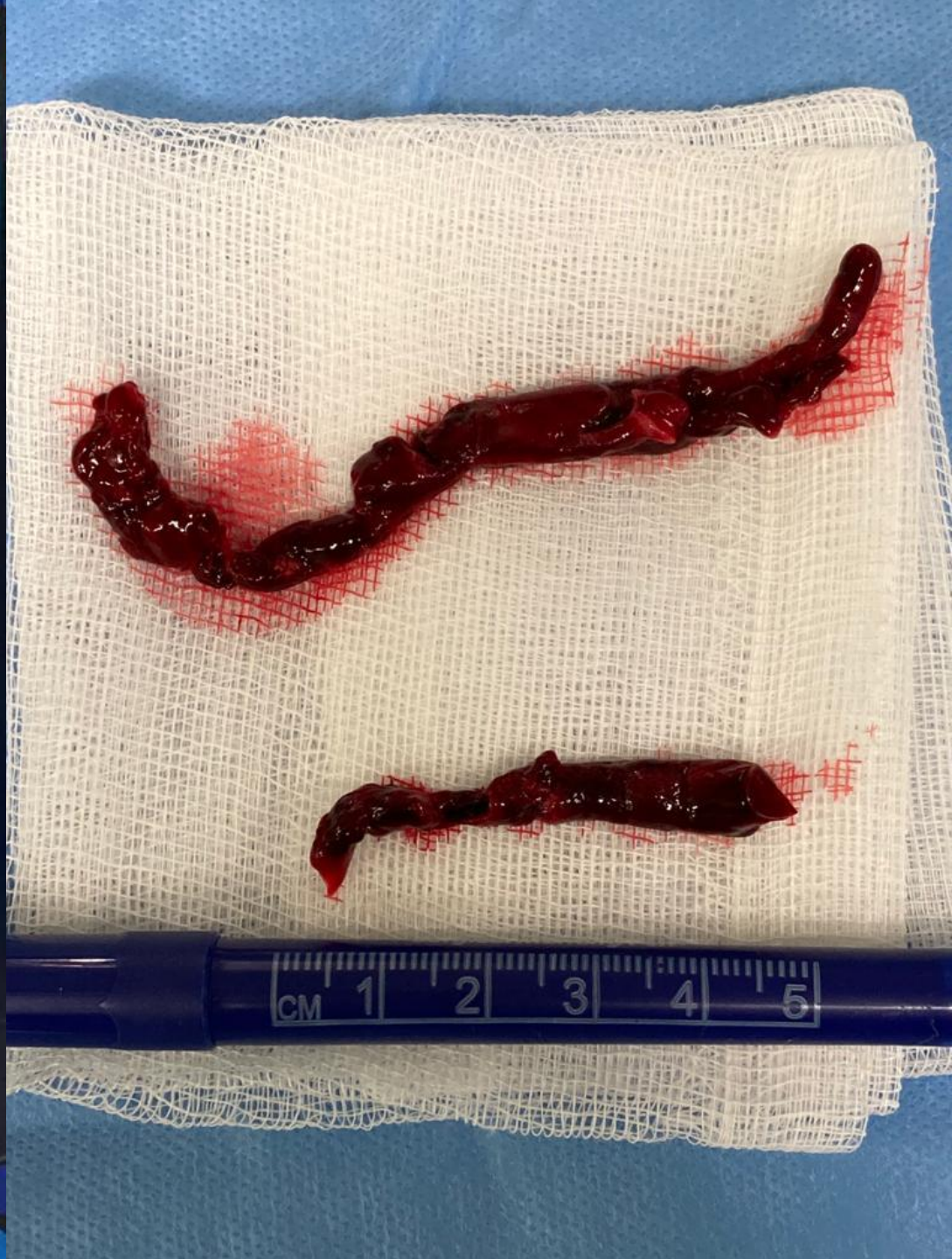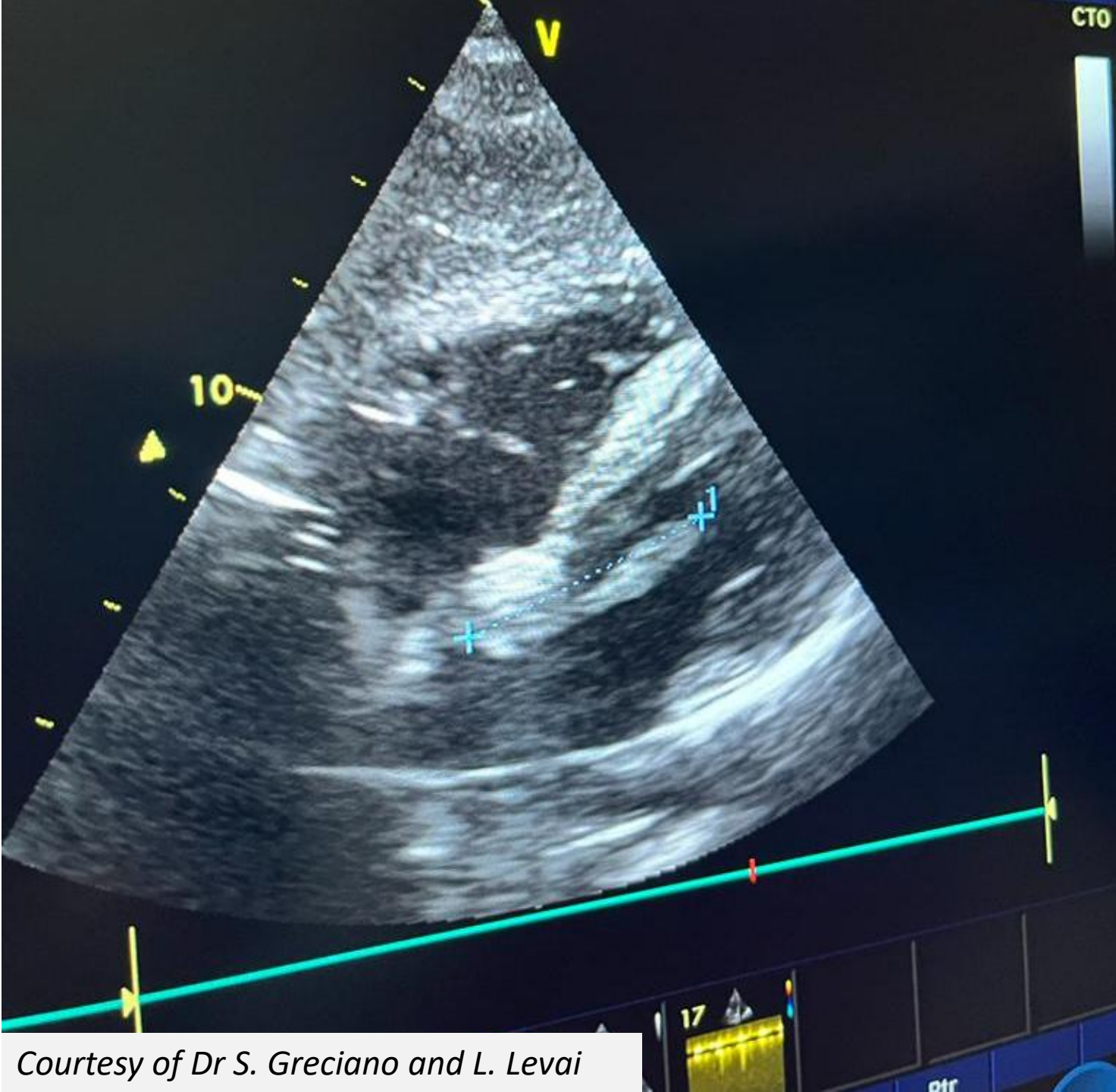
Cas clinique

- Cycliste, virée au lac de Constance (600km!)
- EP au retour
- Infarctus antérieur ensuite



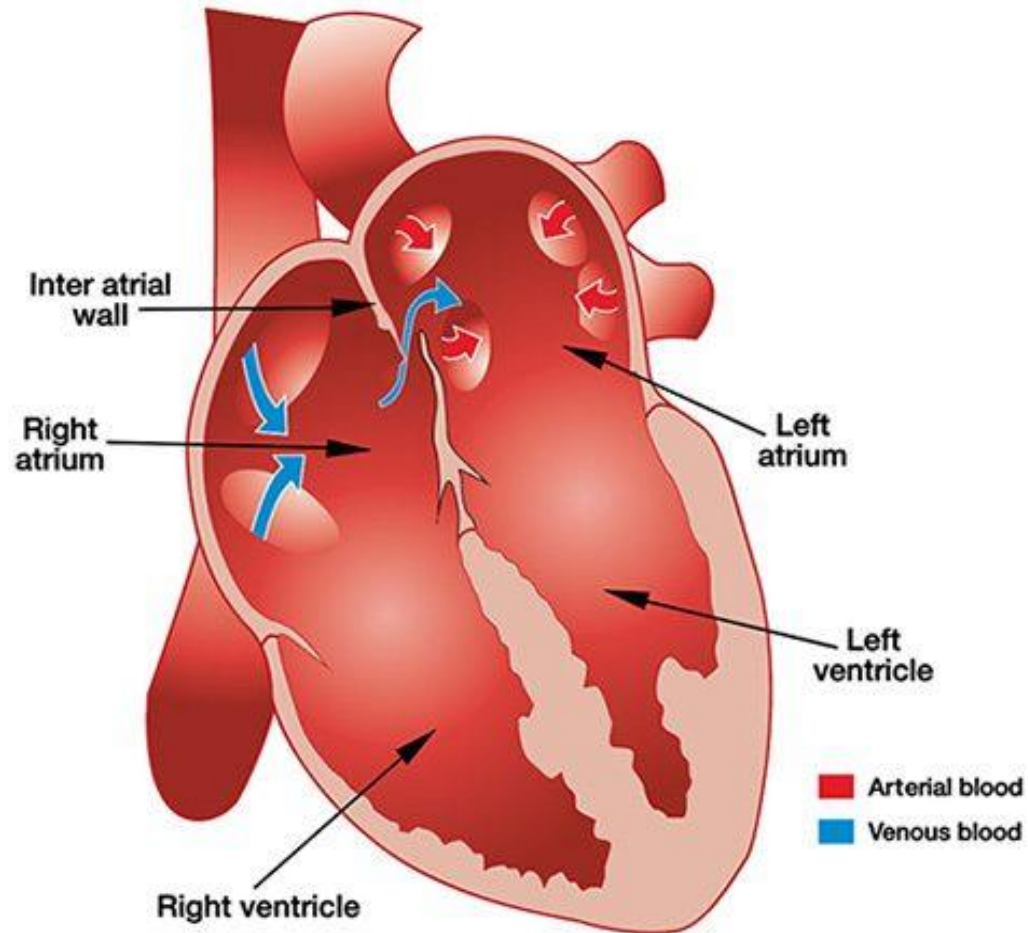
Courtesy of Dr S. Greciano and L. Levai





Courtesy of Dr S. Greciano and L. Levai

Beaucoup de FOP, peu de FOP à haut risque emboligène



27%
of people
with PFO

6%
of people
with large PFO

FOP

Les indications « classiques »

En cas d'AVC cryptogénique, fermer un FOP est inutile et dangereux

Dr Jean-Luc Breda

15 novembre 2010



Commenter

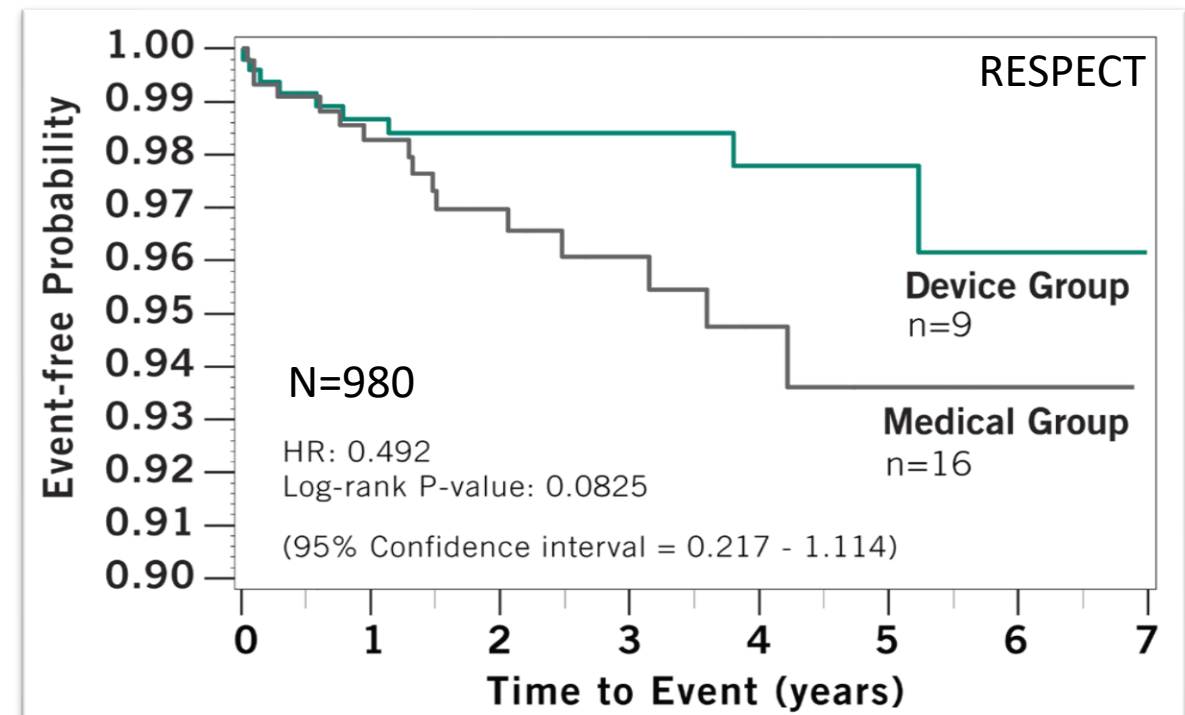
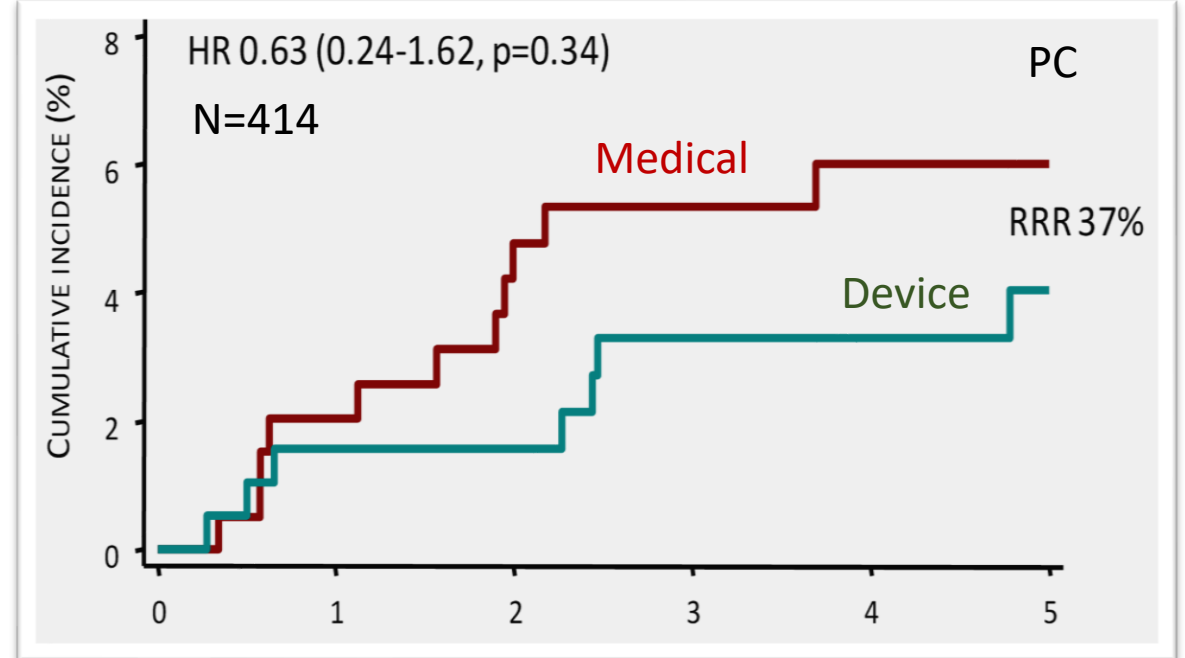
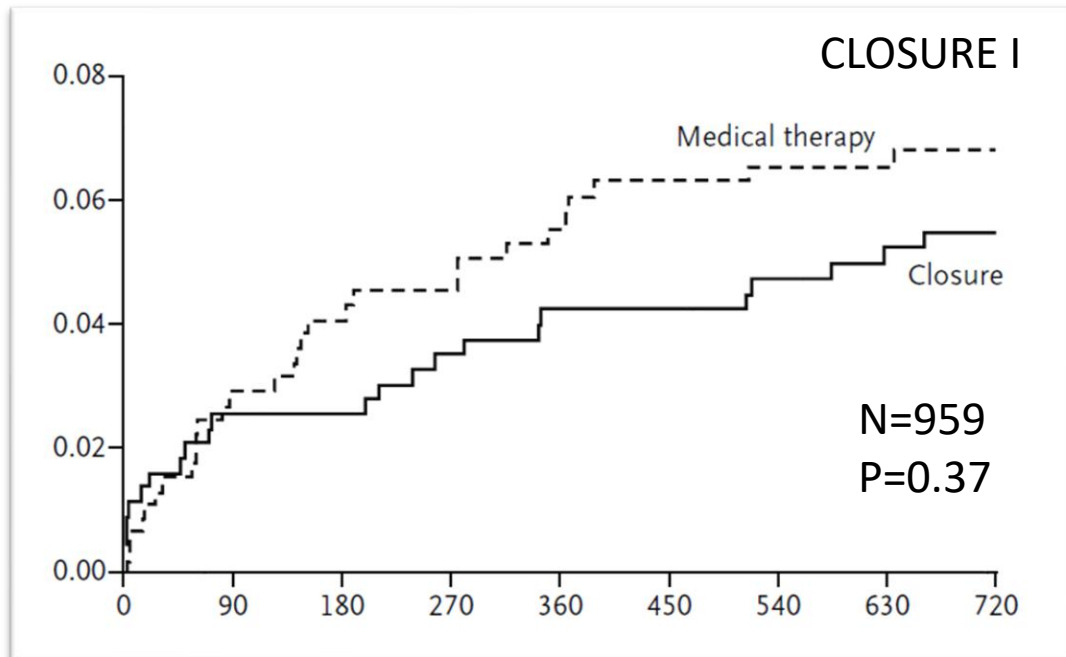


Chicago, IL, É.-U. — La conclusion du **Dr Anthony Furlan** (Cleveland, Ohio) rapporteur de l'étude **CLOSURE 1** lors des sessions scientifiques de l'[American Heart Association 2010](#) est sans appel. ^[1]

« La fermeture d'un foramen ovale perméable (FOP) par un dispositif de type **STARFlex(R)** ne donne pas de meilleurs résultats que le seul traitement médical en terme de prévention des accidents vasculaires cérébraux. Ce geste, non exempt de complications graves, est sans doute pratiqué trop souvent inutilement. »



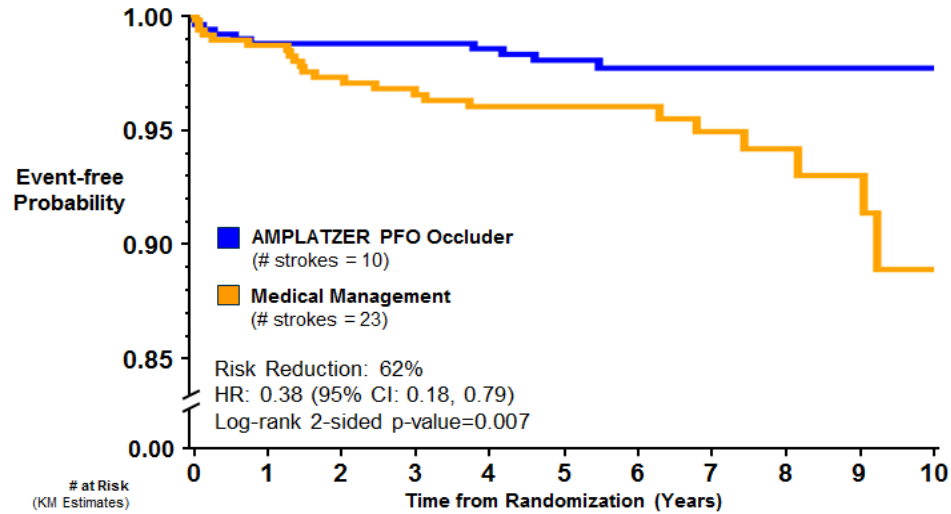
1° EP of three RCTs



2017

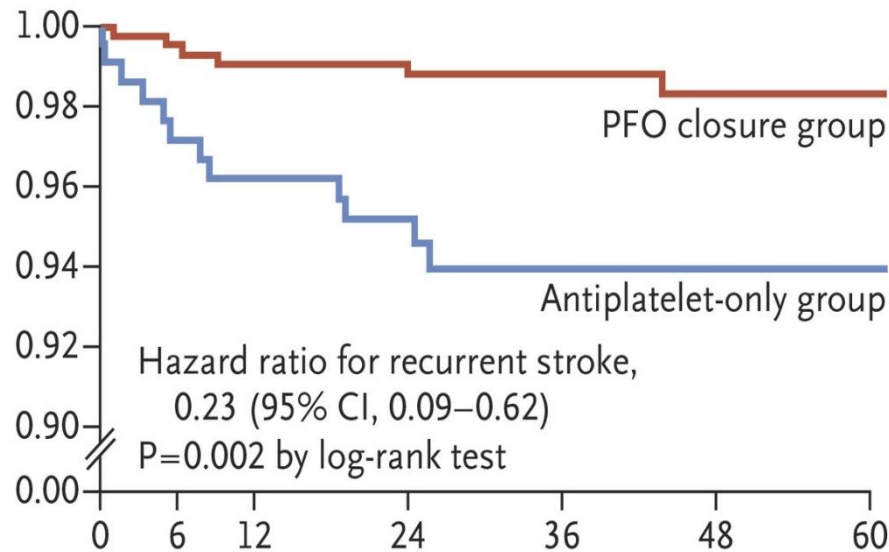
RESPECT Final Results

Freedom from Recurrent Ischemic Stroke of Unknown Mechanism (Intention to Treat)



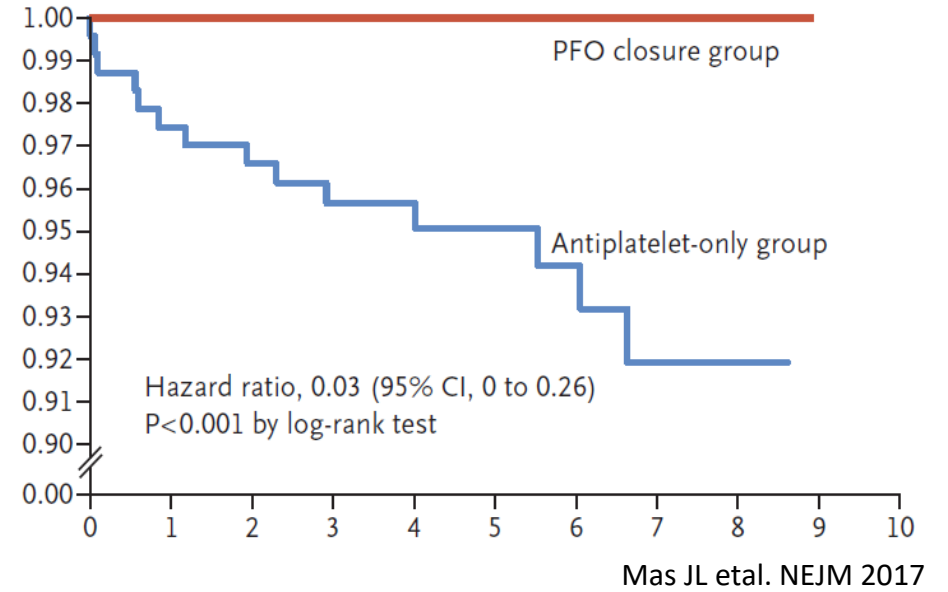
Saver et al. NEJM 2017

Gore-REDUCE



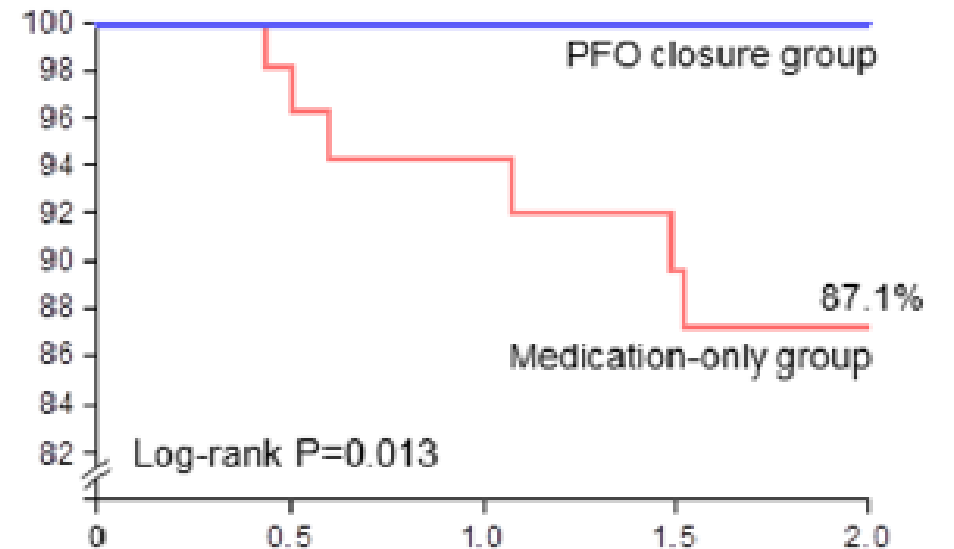
Sondergaard L et al. NEJM 2017

CLOSE



Mas JL et al. NEJM 2017

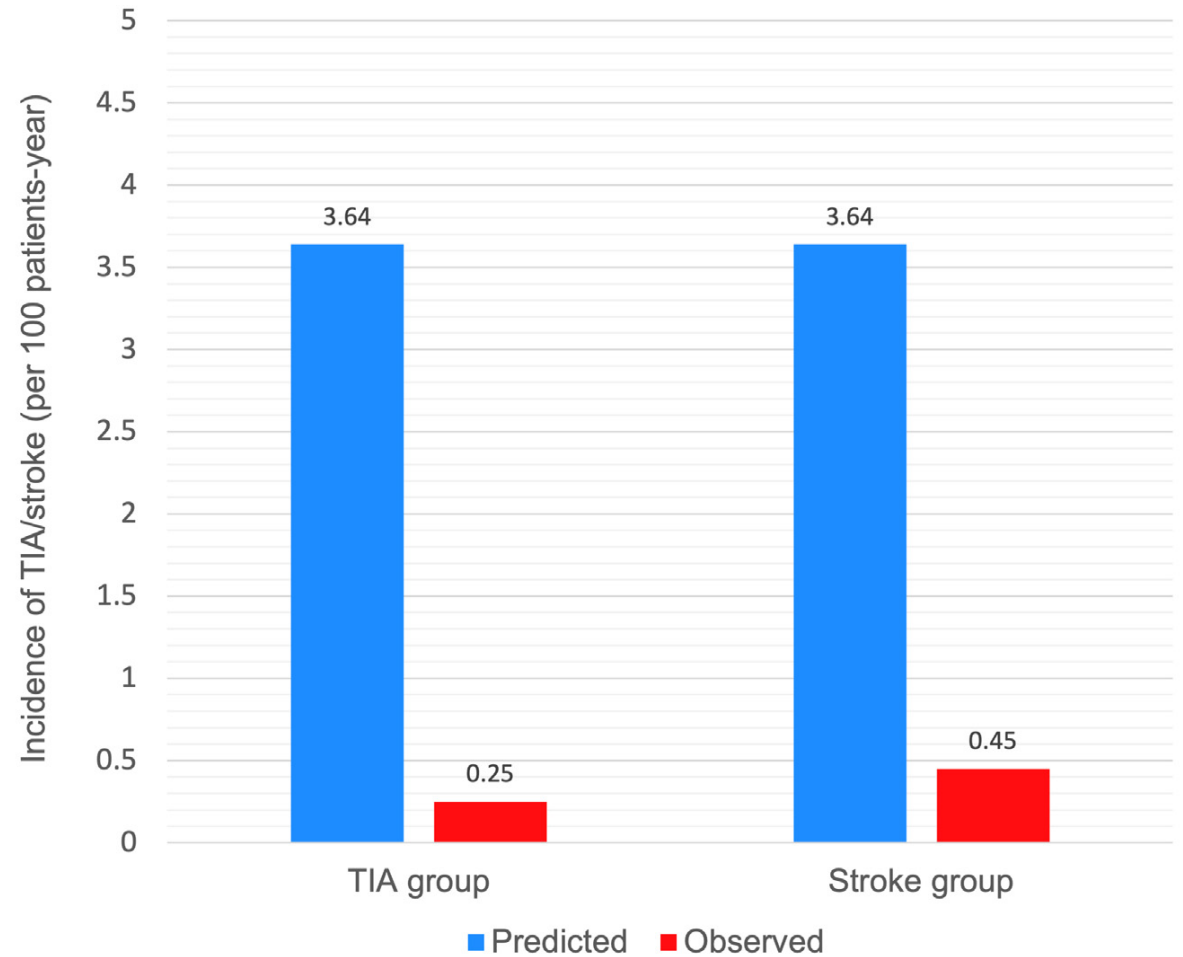
DEFENSE



JACC 2018

TIA ?

- TIA excluded from majority (but not all) RCTs on PFO closure
- Registries in favor of PFO closure for TIAs



Embolies systemiques

PFO closure

Transcatheter PFO closure is recommended in patients fulfilling all the following criteria:

- age 16–60 years
- recent (≤ 6 months) ischaemic stroke (although this delay can be extended if prolonged detection of AF is necessary);
- PFO associated with an ASA (> 10 mm) or with a right-to-left shunt > 20 microbubbles (a large shunt was defined in RCTs by the passage of > 20 , 25 or 30 microbubbles) or a diameter ≥ 2 mm;
- PFO felt to be the most likely cause of the stroke after a thorough aetiological evaluation by a stroke specialist (see Tables A1, A2 and A3).

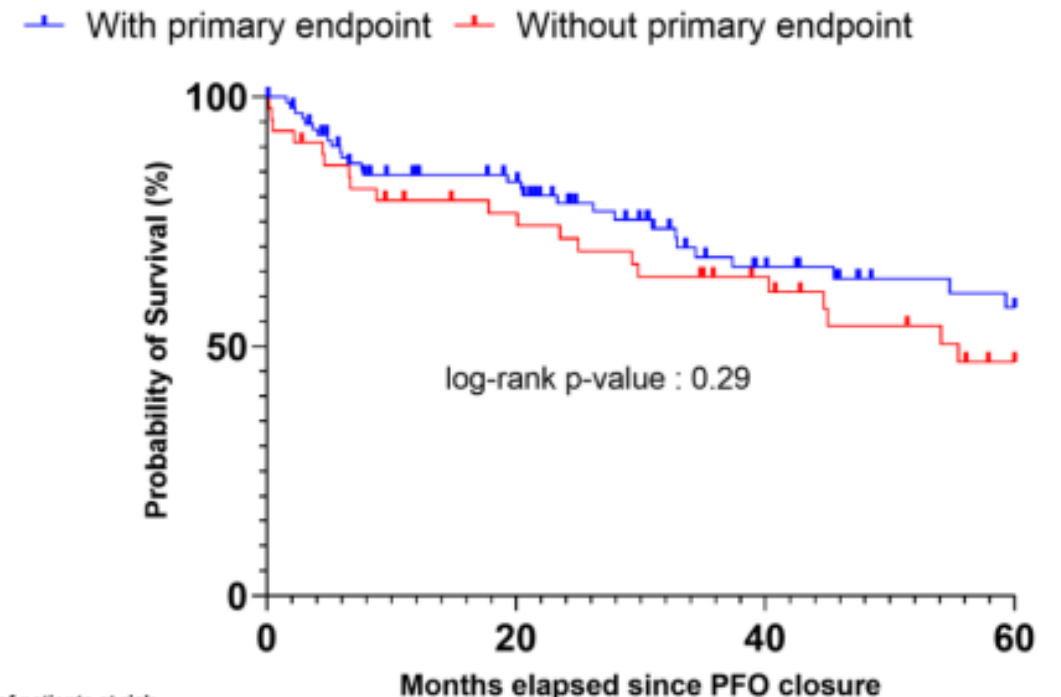
Arch Cardiovasc Dis. 2019;112(8-9):532-542

« The position of our societies is to perform percutaneous closure of a PFO in carefully selected patients aged from 18 to 65 years with a confirmed cryptogenic stroke, TIA, or systemic embolism and an estimated high probability of a causal role of the PFO as assessed by clinical, anatomical and imaging features. »

EuroIntervention 2019;14:1389-1402

Platypnea-orthodeoxia / Hypoxia

- 160/1748 PFO closure procedures, for hypoxemia
- Success: device implanted without major complication + improvement in gas exchange + improvement in dyspnea \geq one-stage
- Success in 106/160 (66%)

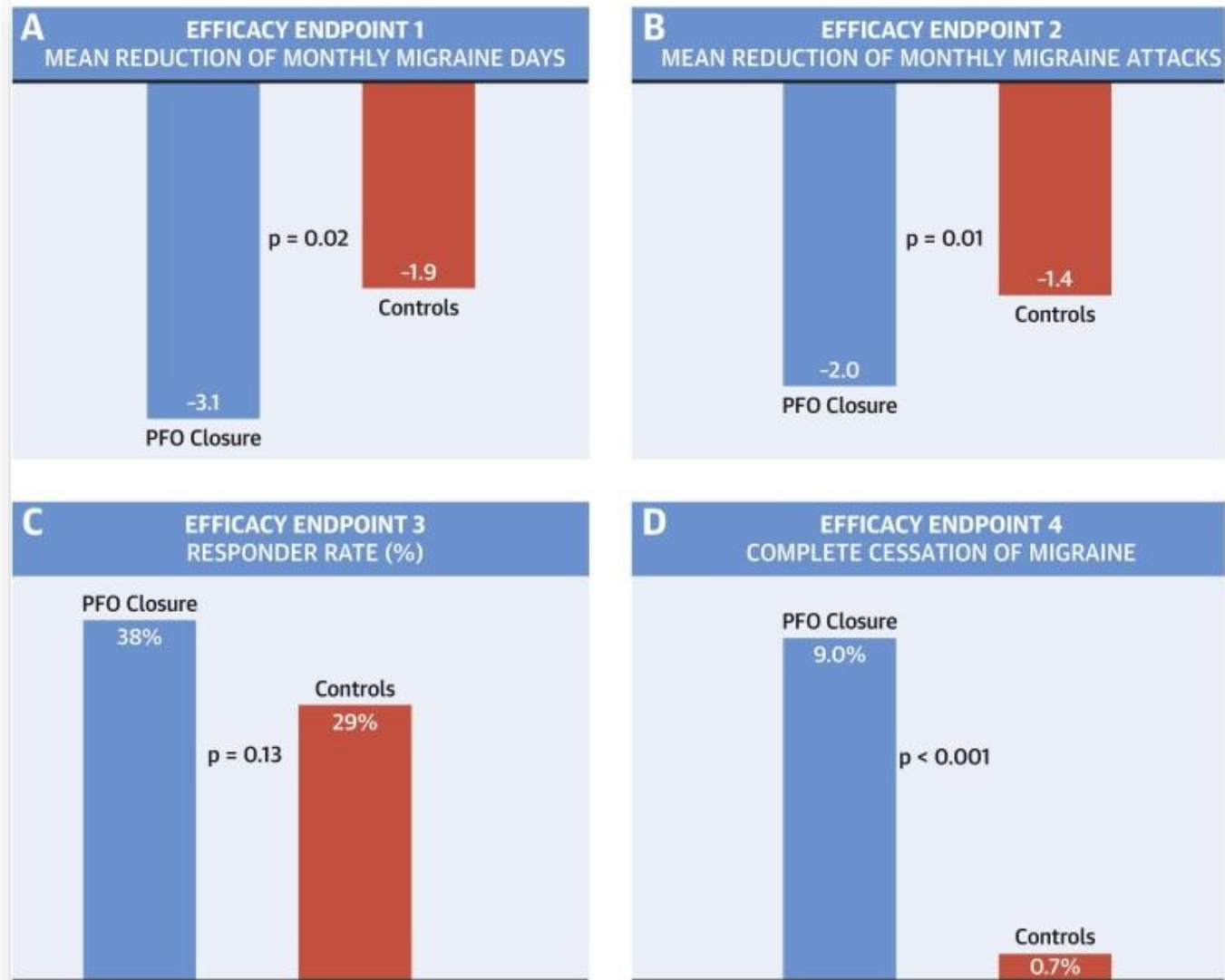


Number of patients at risk	0	20	40	60
With primary endpoint	94	62	32	20
Without primary endpoint	44	31	22	11

FOP

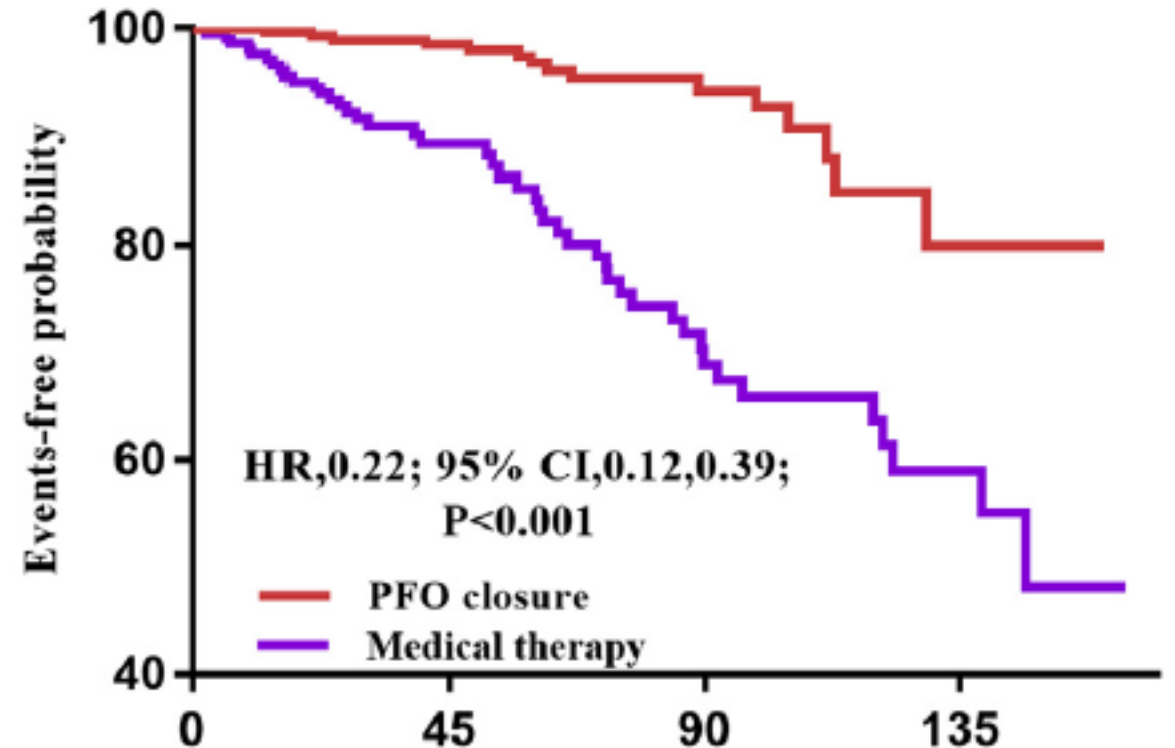
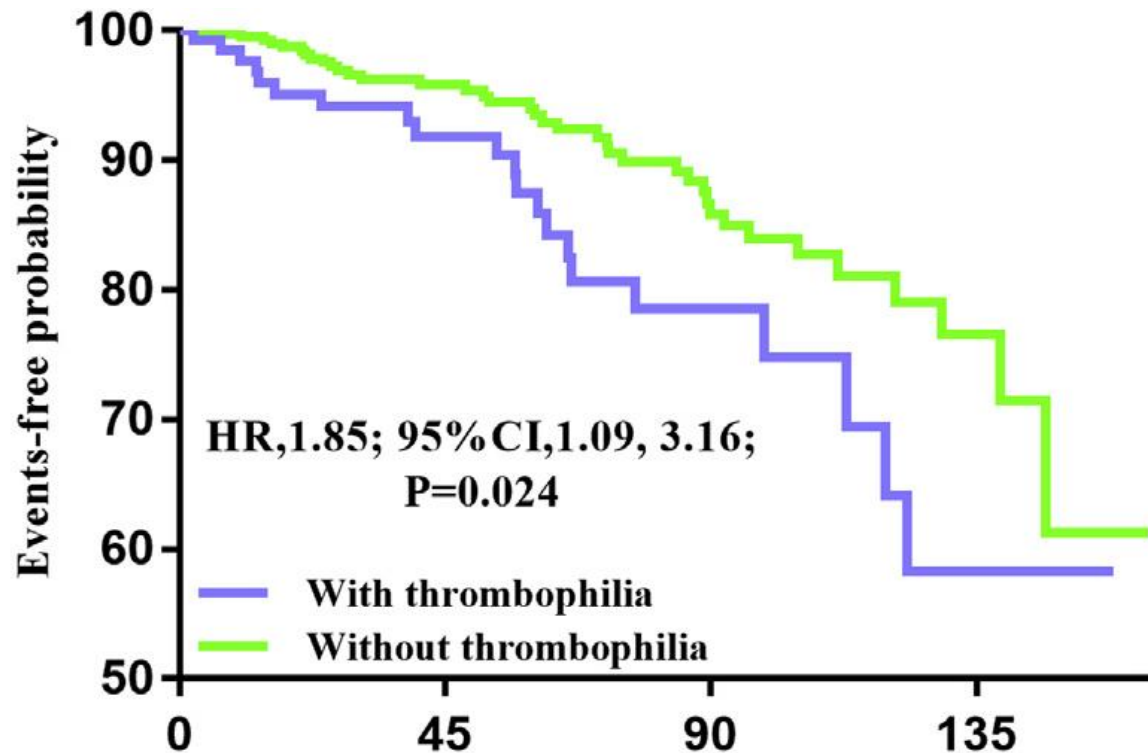
Les indications « discutées »

FOP et Migraines



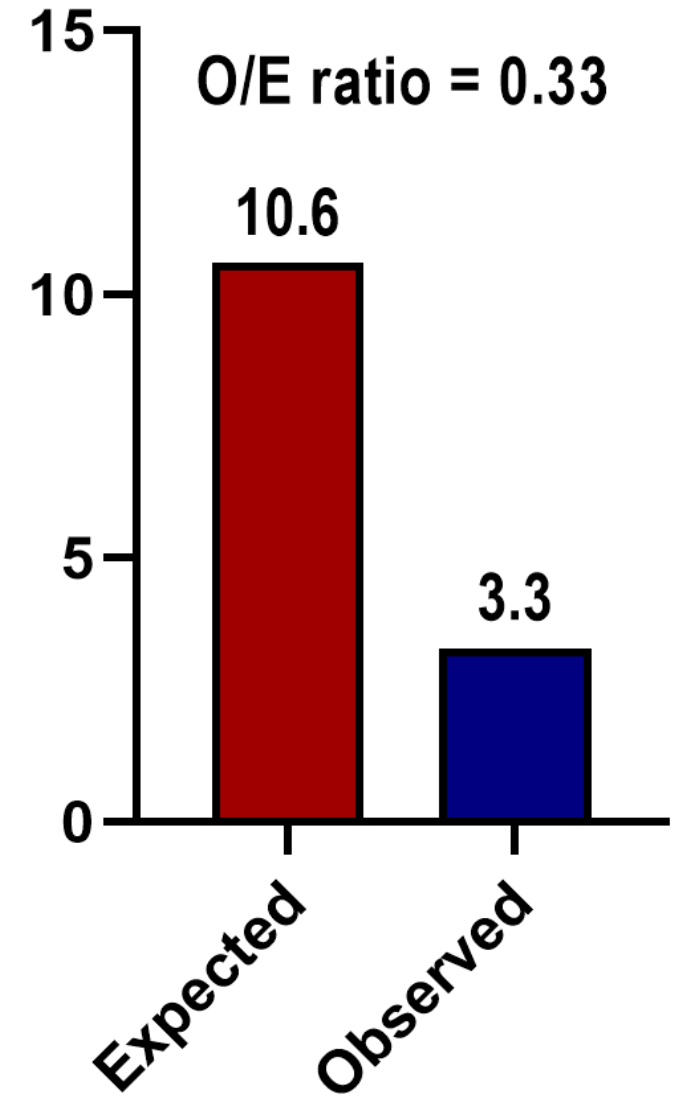
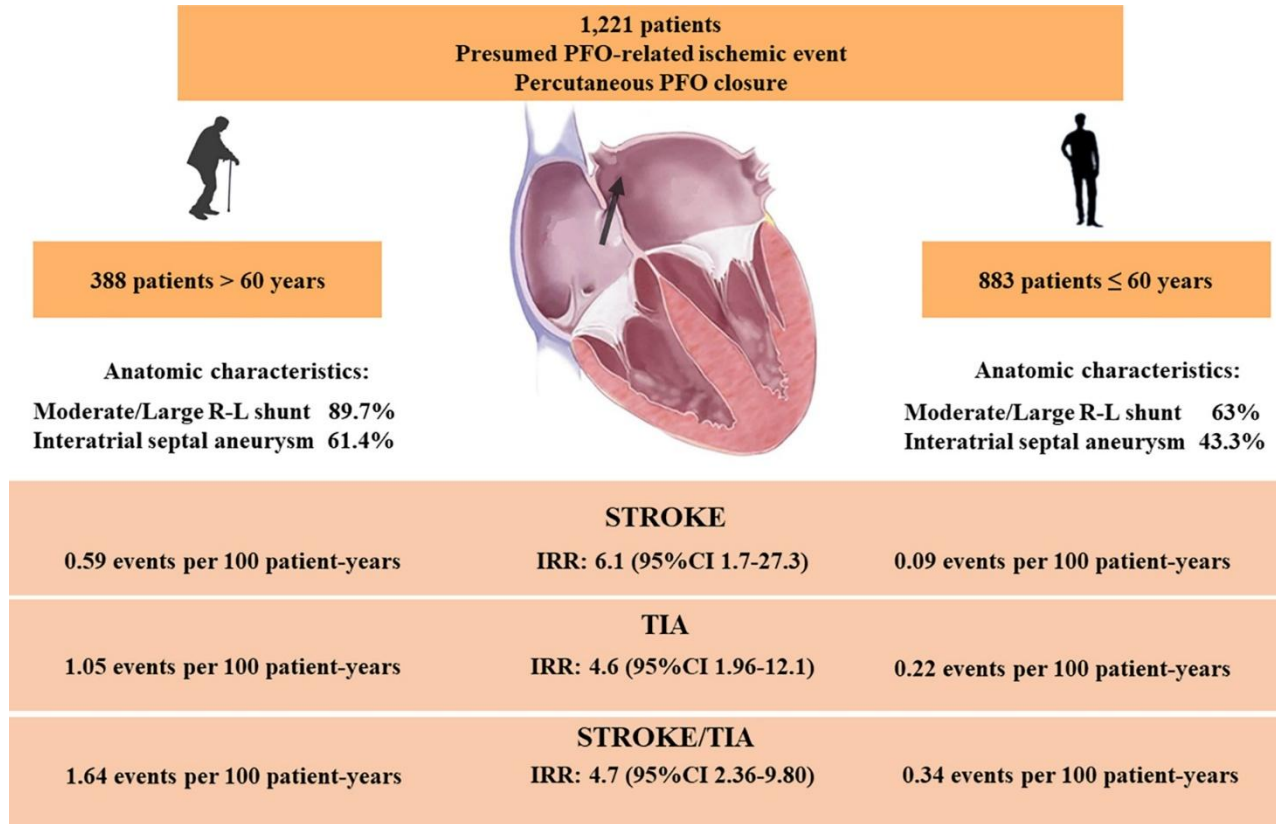
FOP et Thrombophilie

cryptogenic stroke or TIA with PFO



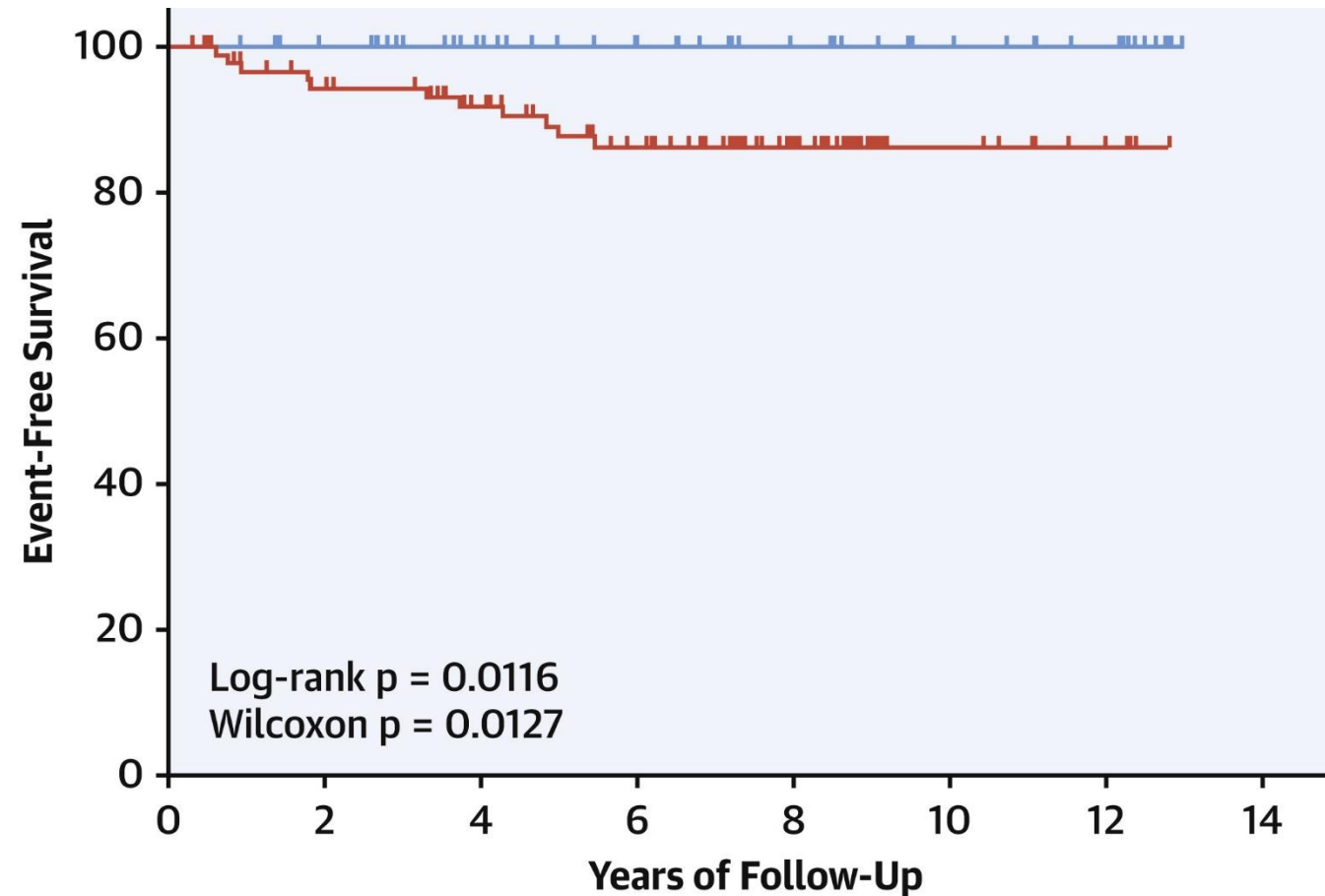
In patients with thrombophyllia, recurrent stroke/TIA (6.7%) with PFO closure versus (33.3%) with medical treatment (HR 0.23; 95% CI: 0.09 to 0.61; p = 0.003)

Older patients



FOP et accidents de décompression

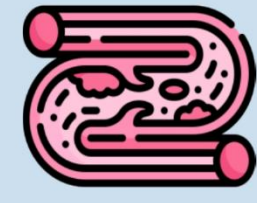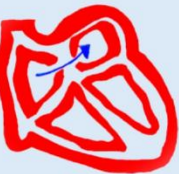829 consecutive divers were prospectively included in the DIVE-PFO registry: high-grade PFO was diagnosed in 153 (22%) divers → 55 had PFO closed → 7-yr FU : unprovoked DCS



No. at risk:

	0	2	4	6	8	10	12
— Closure Group	55	50	41	34	25	16	11
— Conservative Group	98	83	71	57	34	11	6

PFO closure in the OLDW cohort (n=5315)



Decompression Illness

non-stroke patients:0.3%

✓ **First line:**
behavioural diving changes

✓ **Consider closure:**
Secondary prevention if provocative diving continues

x PFO screening

x **Routine closure** as primary/secondary prevention

Chronic Migraine

non-stroke patients:8.8%

✓ **First line:**
Optimise pharmaceutical treatment

✓ **Consider closure:**
Persistent migraine with aura

x **Routine closure**

Thrombophilia

stroke patients:6.3%
Non-stroke patients:1.4%

✓ **Consider closure:**
Add-on to antithrombotics for secondary stroke prevention

x **Routine closure** for primary stroke prevention

Patients >60 years old

stroke patients:29.2%

✓ **Consider closure:**
Risk factor and overall health evaluation

x **Routine closure** after PFO-associated stroke



FOP

Les indications « discutables »

Prévention primaire

- 4 sœurs
- 3 avec FOP fermé pour AIC
- 4^{ème} sœur: FOP à ETTc sans AIC (IRM normale)
- Demande de fermeture en prévention 1^{aire}

- Patient 55ans
- ATCD EP
- SAOS appareillé
- Mauvaise tolérance nocturne → FOP

- 2 frères jumeaux
- 1 FOP fermé pour AIC
- 2^{ème} frère: FOP à ETTc sans AIC (IRM normale)
- Demande de fermeture en prévention 1^{aire}

- Patient 28ans
- Haltérophile
- Varices et phlébites
- ETO pour IM → FOP!

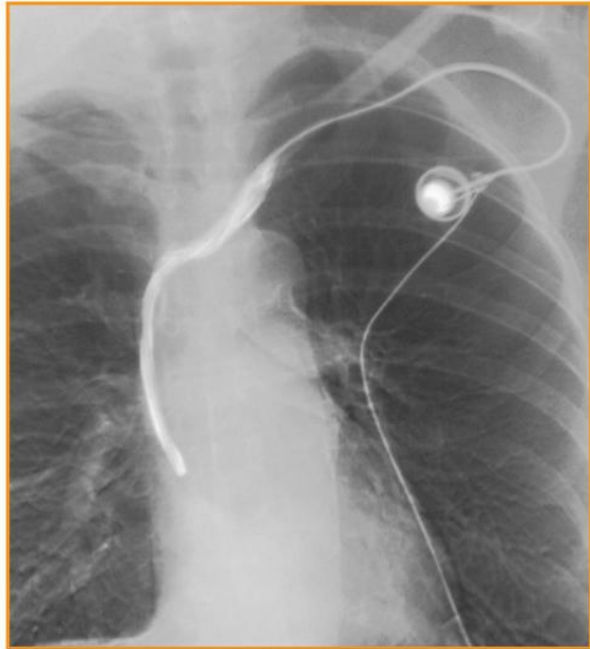
- Patiente 44ans
- ATCD: MVTE; pas d'AIC
- FOP connu chez elle et sa sœur (AIC)
- K sein / tamoxifène

FOP

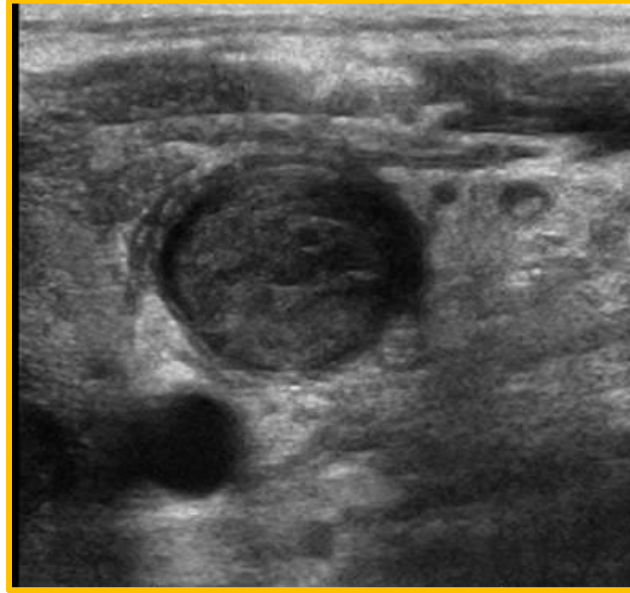
Les indications « atypiques »

FOP et thrombose de matériel OD

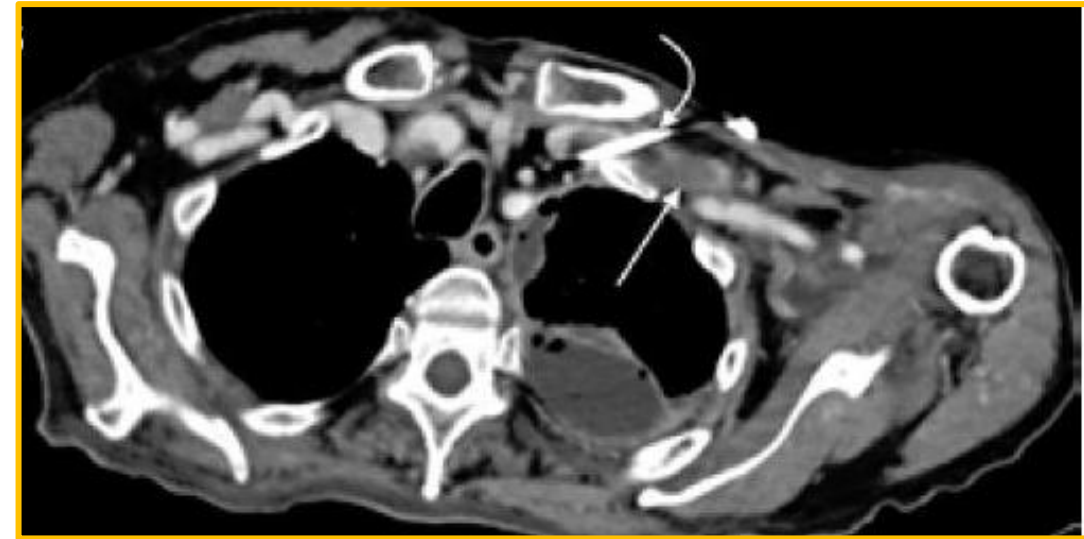
(port-a-cath, cathéter veineux central, sonde PM...)



Thrombose étendue sur
port-à-cath



Thrombose de veine
jugulaire interne

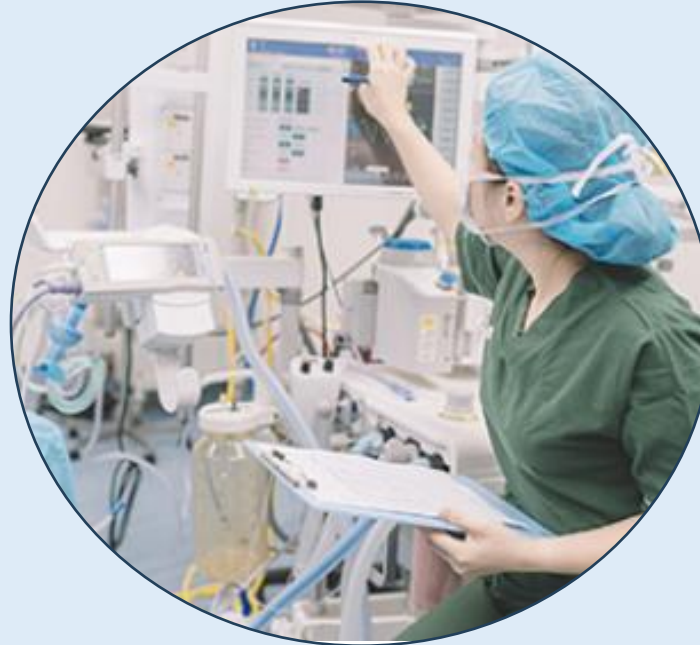

Thrombose de veine sous-clavière G sur sonde PM

FOP et AG

Embolie gazeuse per-op

Neurochirurgie en position assise
Coelioscopie
Chirurgie robot-assistée



Hypoxémie post-op

Extubation impossible
Hypoxémie réfractaire

« Connaissance d'un Foramen Ovale perméable (FOP) lors d'une exploration dans les suites d'un AVC ou d'une hypertension pulmonaire : **discussion sur l'insufflation et donc la robotique pour le risque d'embolie gazeuse paradoxale** »

FOP et neurochirurgie en position assise

Table 1. Overview of Studies Published After 2007 Reporting on Paradoxical Embolism in Patients Who Underwent Surgery of the Cervical Spine or Posterior Fossa in the Semi-Sitting Position with a Known Patent Foramen Ovale

Study	Number of Patients	Air Embolism, Number (%)	Method of Detection	Paradoxical Embolism, Number
Ammirati et al., 2013 ⁴	4	0	Precordial Doppler, air aspiration	0
Hervías et al., 2014 ⁶	2	0	Precordial Doppler	0
Ganslandt et al., 2013 ⁵	24	4 (16.6)	Precordial Doppler/TEE	0
Feigl et al., 2014 ⁷	52	29 (55.7)	TEE	0
Total	82	33 (40.2)		0

TEE, transesophageal echocardiography.

40,2%

Après recherche d'un FOP, il est probable que certaines opérations aient été faites en position horizontale (sous estimation du risque EG)

Recherche de FOP pour ce type de chirurgie et décision collégiale: position horizontale ou fermeture de FOP ou fermeture sélective de FOP (large, shunt massif, etc...)

FOP

Les indications « d'avenir »



- Peripheral emboli
- Migraines with aura
- Laparoscopic surgery
- Exercise desaturation
- HAPE (high altitude pulmonary edema)
- SAOS
- Deep sea divers
- Astronauts and Jet flyers
- Brass musicians and glass blowers
- Planned pregnancy

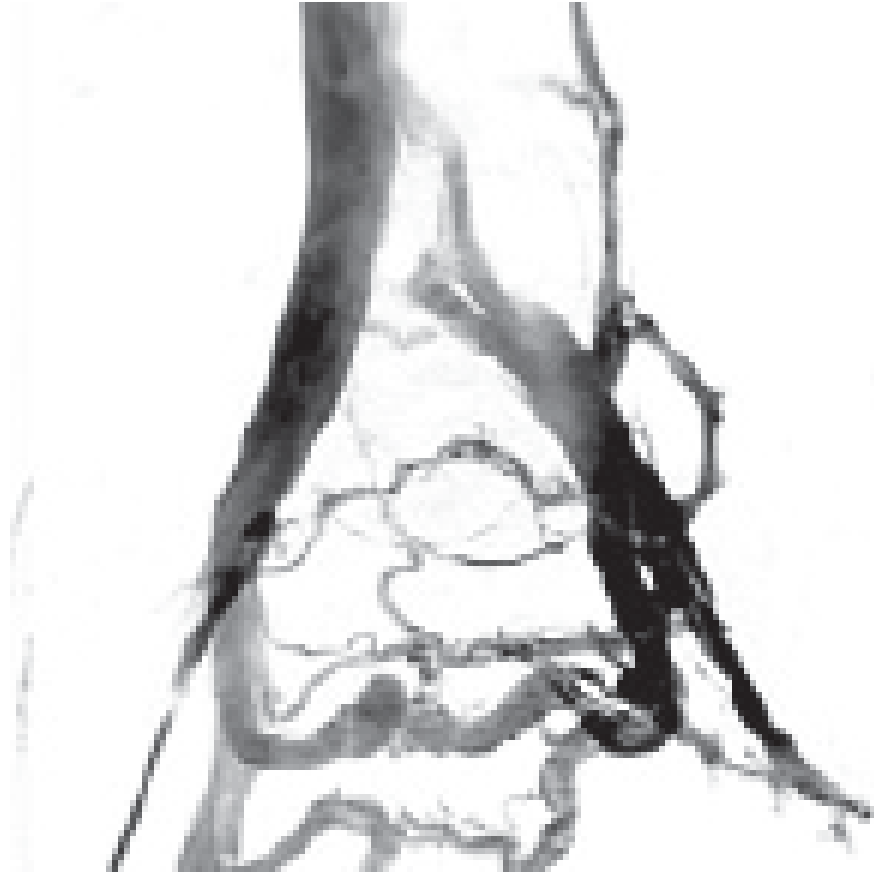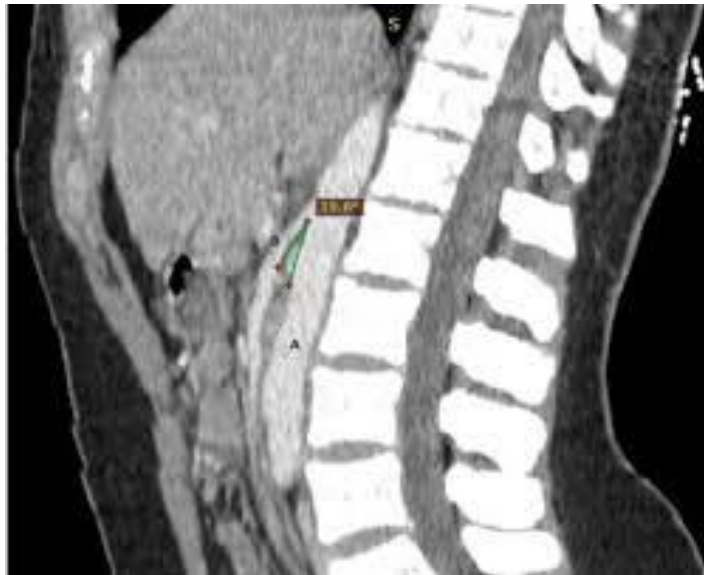
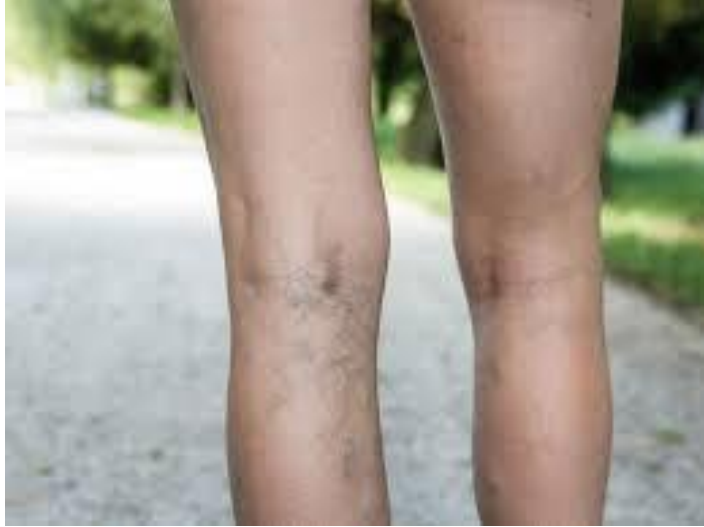FOP

La recherche des **sources d'embolies**

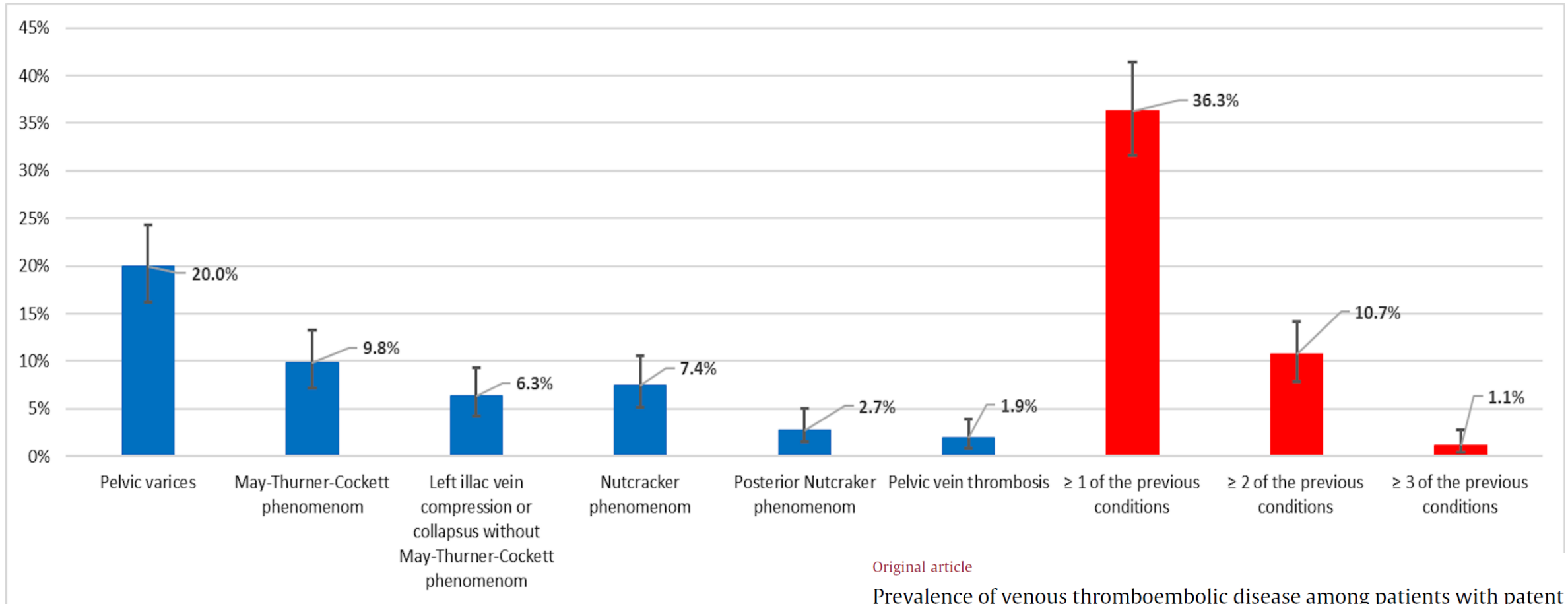
Rechercher:

1. ATCD de MVTE, varices, hémorroïdes et leurs traitements...
2. ATCD de thrombophilie
3. ATCD autre d'embolie
4. Circonstance: immobilisation, voyages, SAS

Interrogatoire - imagerie



Pelvic sources of emboli in PFO patients with a prior ischemic event (MRI)



Original article

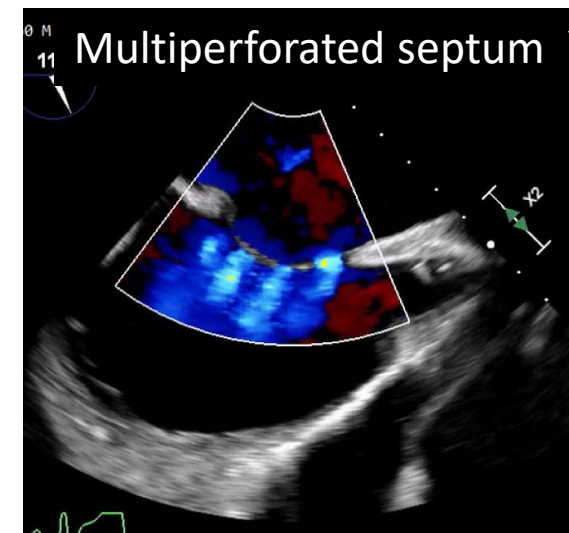
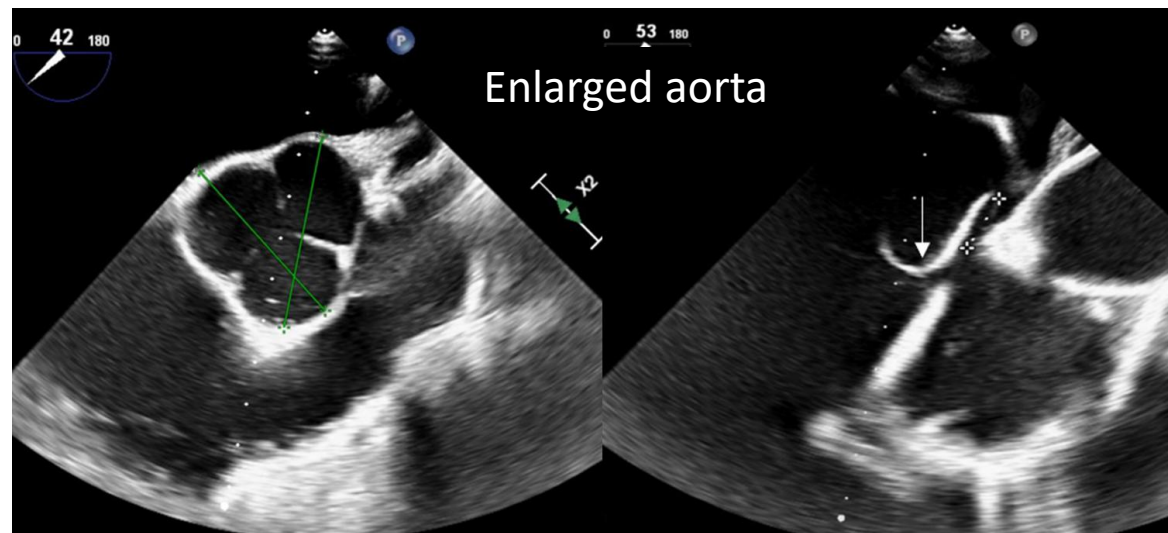
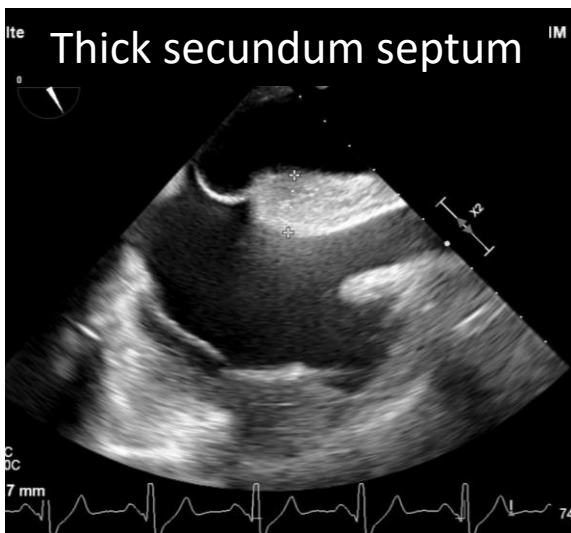
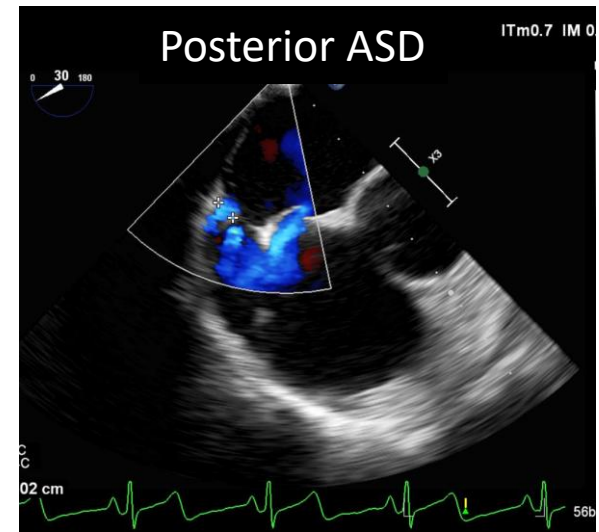
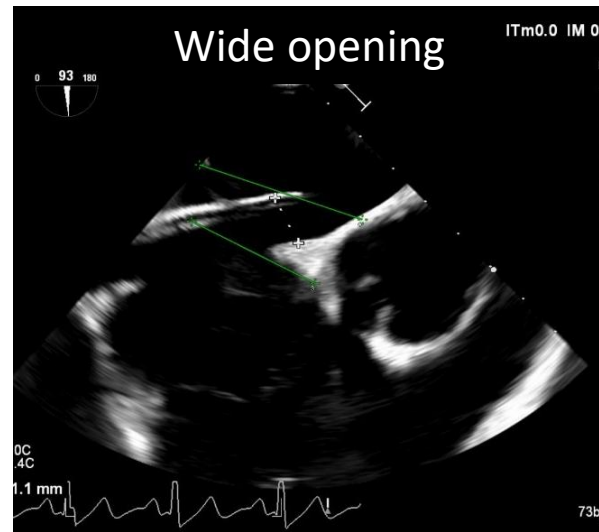
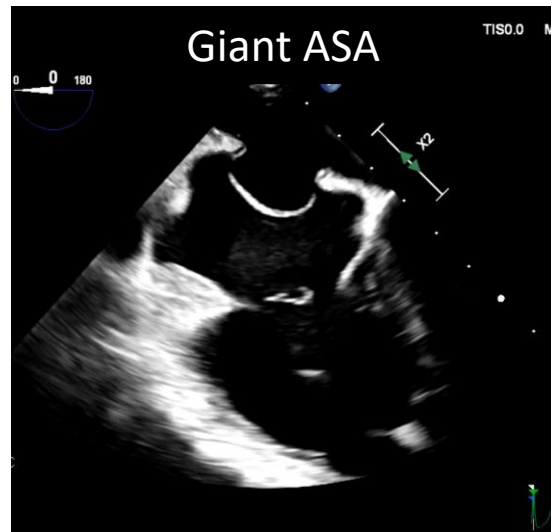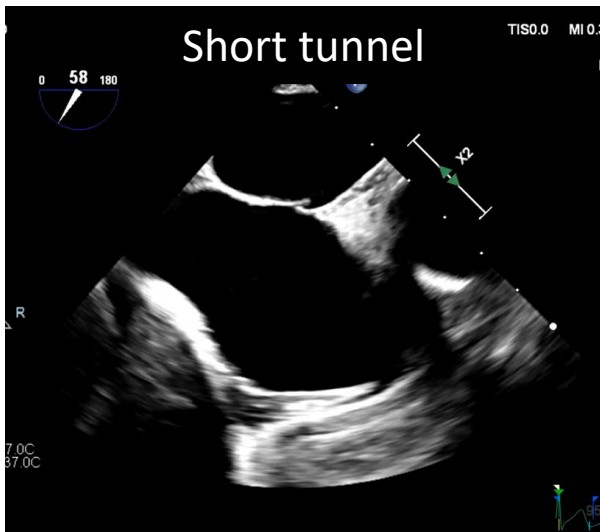
Prevalence of venous thromboembolic disease among patients with patent foramen ovale-related arterial ischemic events

Gabriel Chevrot,^{a,b} Gilles Montalescot,^{a,b,*} Schahrazed Larbi-Messaoud,^{c,d} Perrine Devos,^{a,b} Niki Procopi,^{a,b} Michel Zeitouni,^{a,b} Etienne Charpentier,^{c,d} Marie Dupuy,^{a,b} Lan Anh Nguyen,^{c,d} Sonia Alamowitch,^e Charlotte Rosso,^e Sophie Crozier,^e Anne Léger,^e Clemence Blanc,^e Jean Capron,^f Michaël Obadia,^g Candice Sabben,^g Stéphanie Rouanet,^{b,h} Nadjib Hammoudi,^{a,b} Dan Toledano,^{c,d} Samia Boussouar,^{c,d} Johanne Silvain,^{a,b} Alban Redheuil,^{c,d} and Paul Guedeney^{a,b}

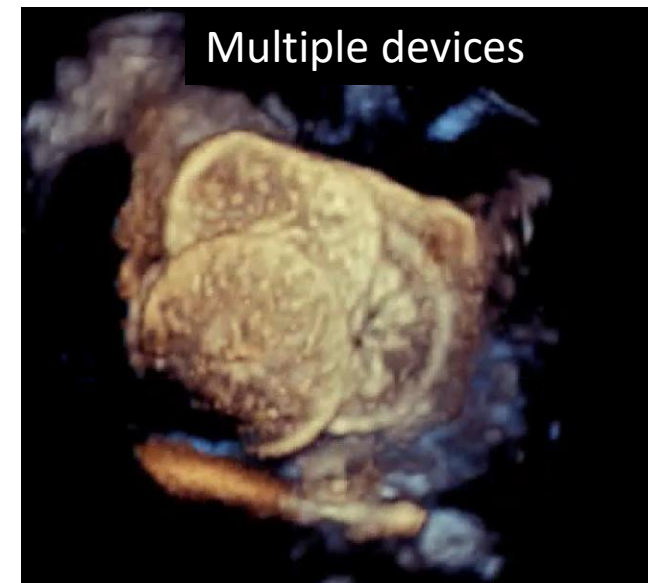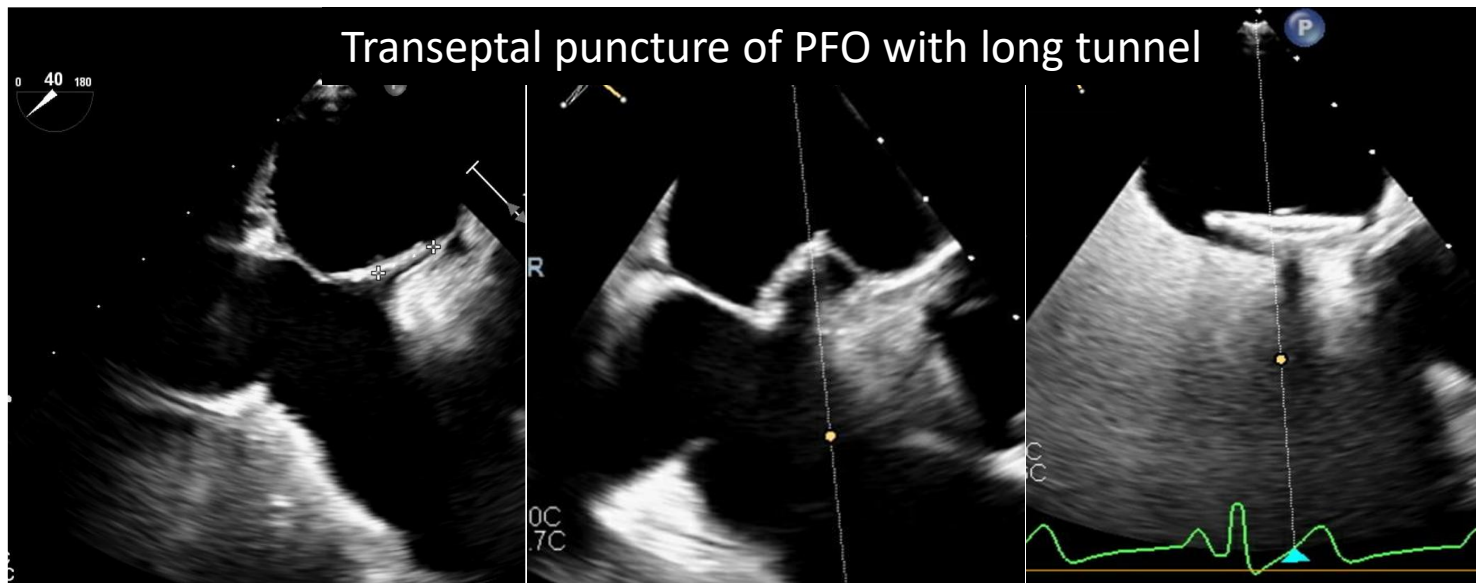
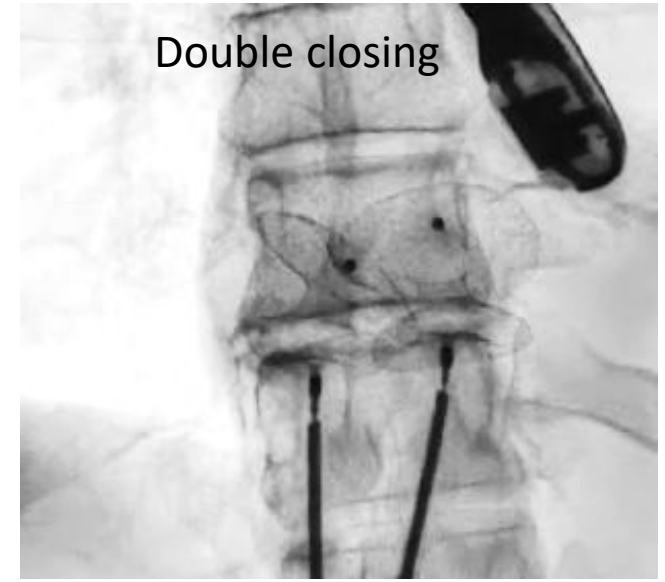
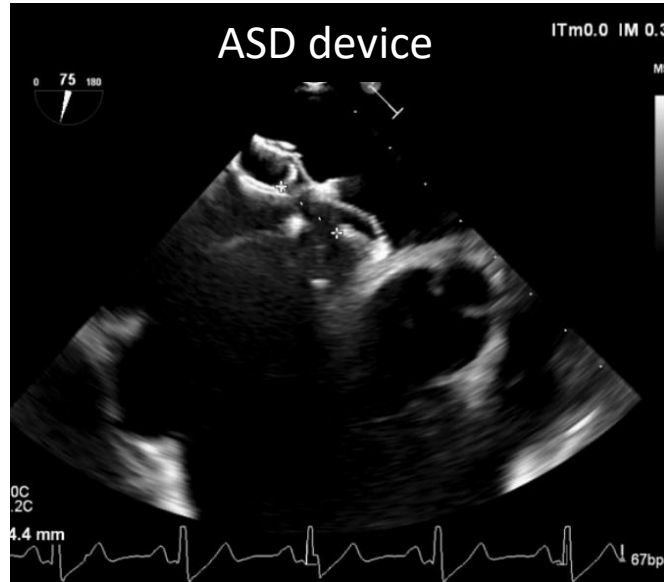
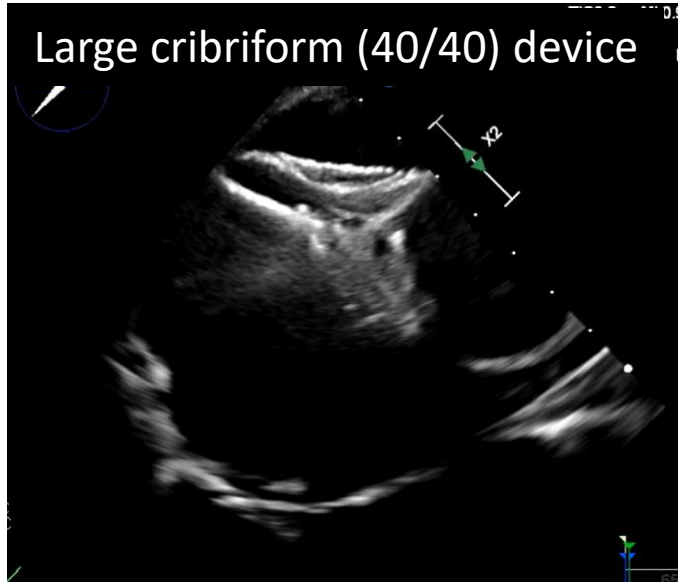
FOP

La fermeture de FOP complexes

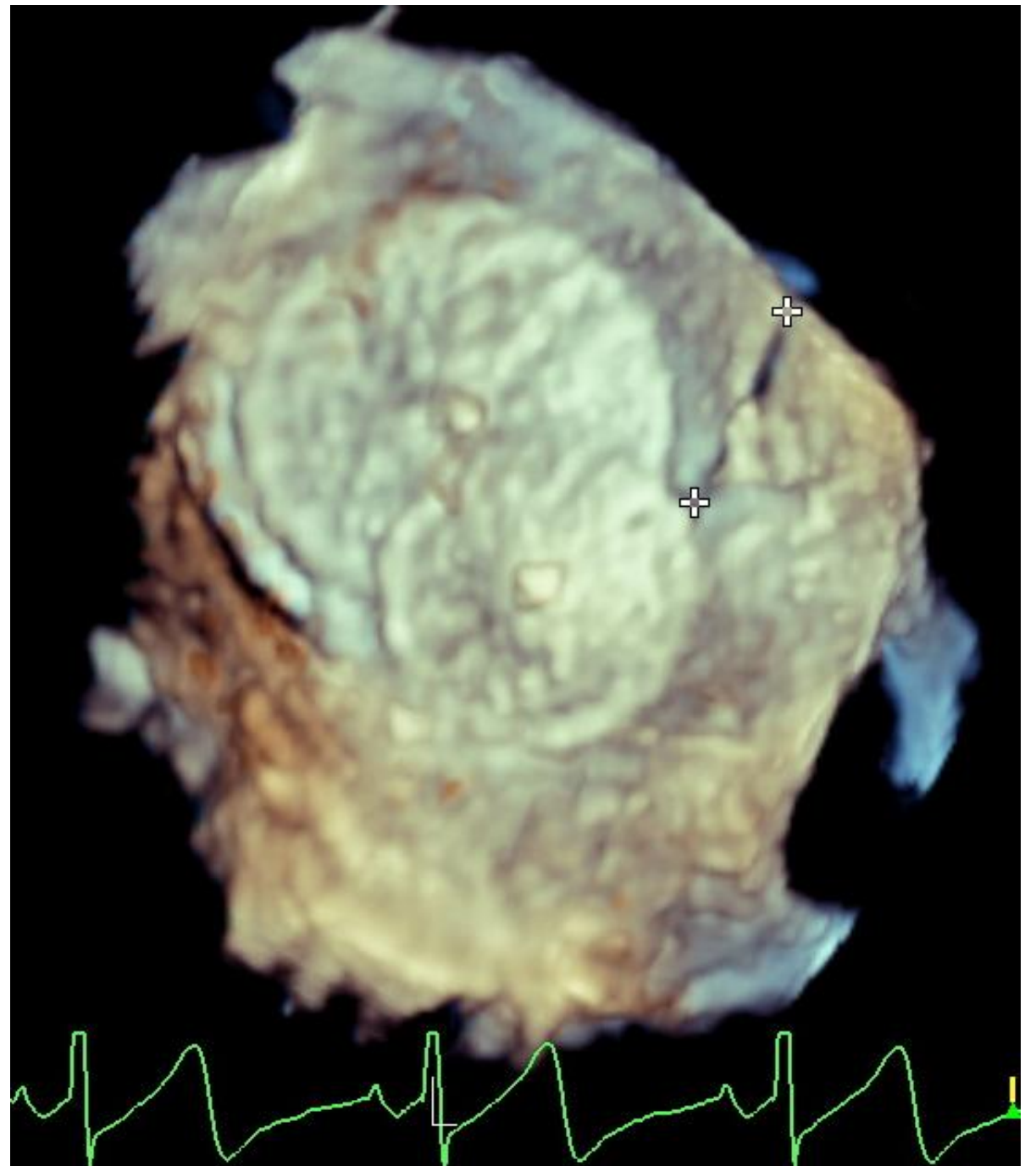
Reconnaitre les situations à risque



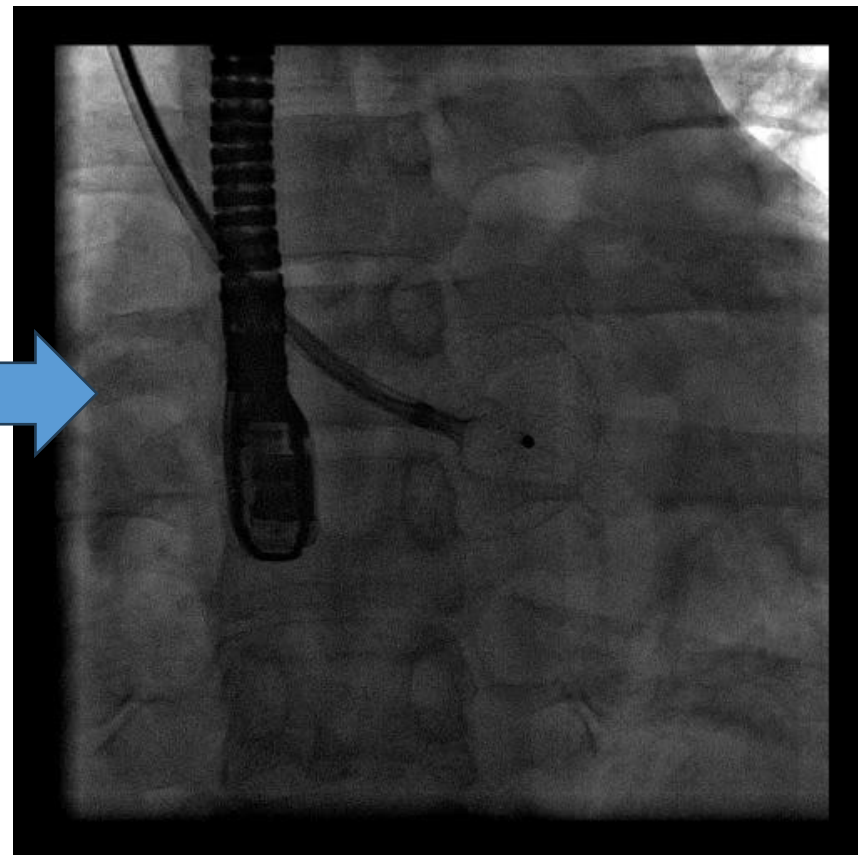
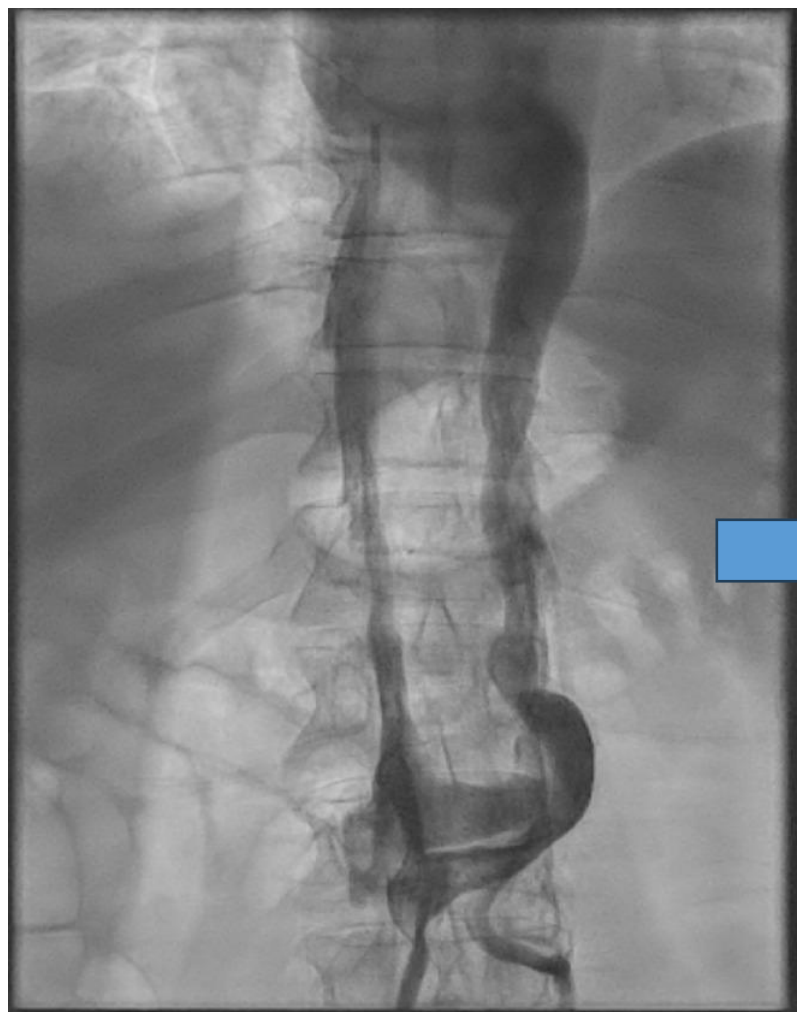
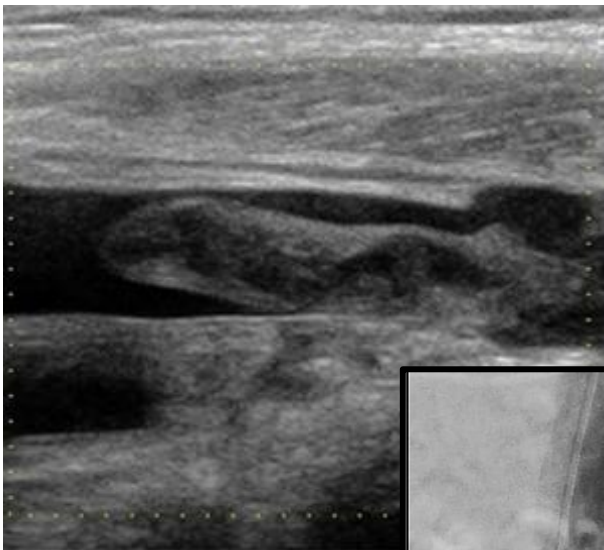
Options techniques



Fente de septum



Accès au FOP



FOP

Et après la fermeture de FOP?

Traitement antiplaquettaire

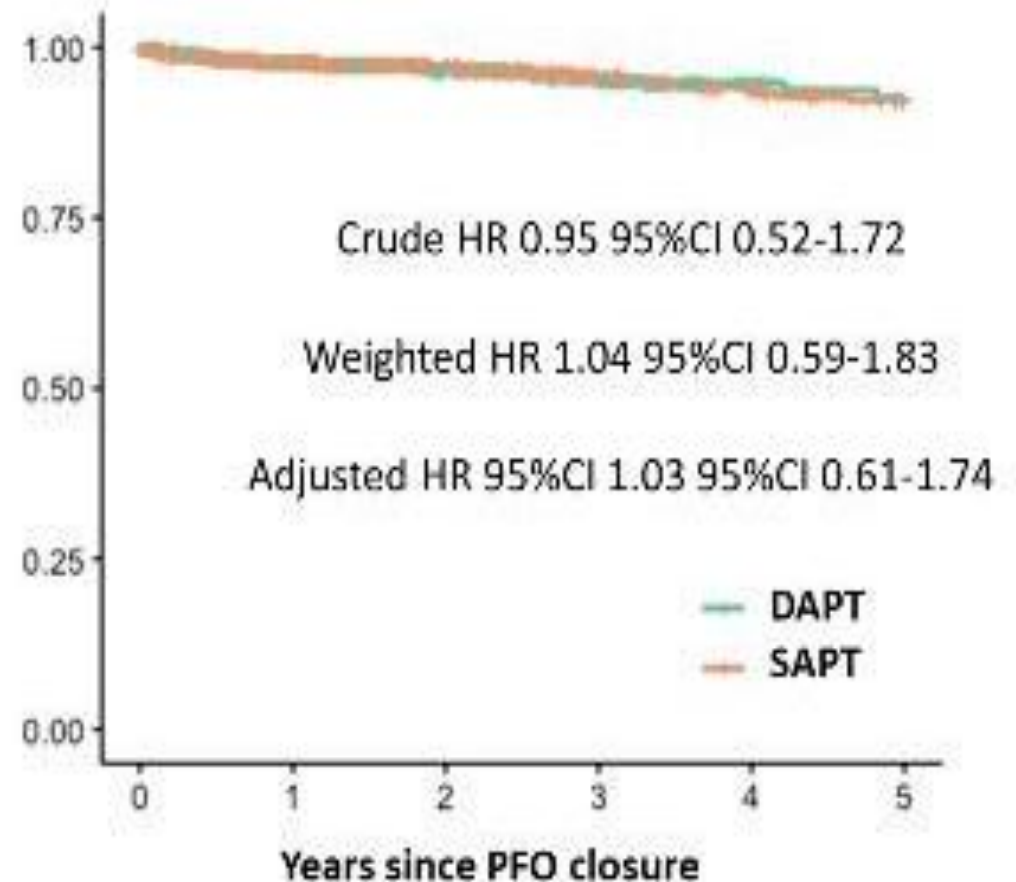
- **Dual antiplatelet therapy at discharge**
 - 933 patients mostly from French centers
 - DAPT Duration: 3 months or less in 96.9% of the cases
- **Single antiplatelet therapy at discharge**
 - 599 patients mostly from Canadian center
 - ASA in 89.3% of the cases

Impact of the antiplatelet strategy following patent foramen ovale percutaneous closure [Get access >](#)

Paul Guedeney, Julio I Farjat-Pasos, Gabriel Asslo, Vincent Roule, Farzin Beygui, Alexis Hermida, Paul Gabrion, Laurent Leborgne, Christine Houde, Florent Huang, Benoit Lattuca, Florence Leclercq, Jules Mesnier, Jérémie Abtan, Stéphanie Rouanet, Nadjib Hammoudi, Jean-Philippe Collet, Michel Zeitouni, Johanne Silvain, Gilles Montalescot ✉, Josep Rodés-Cabau, for the AIR-FORCE Task Force

European Heart Journal - Cardiovascular Pharmacotherapy, pvad023, <https://doi.org/10.1093/ehjcvp/pvad023>

Survival free of death, stroke, TIA, peripheral arterial embolism, MI, or BARC type ≥ 2 bleeding



Risque de FA

Supraventricular Arrhythmia Following Patent Foramen Ovale Percutaneous Closure

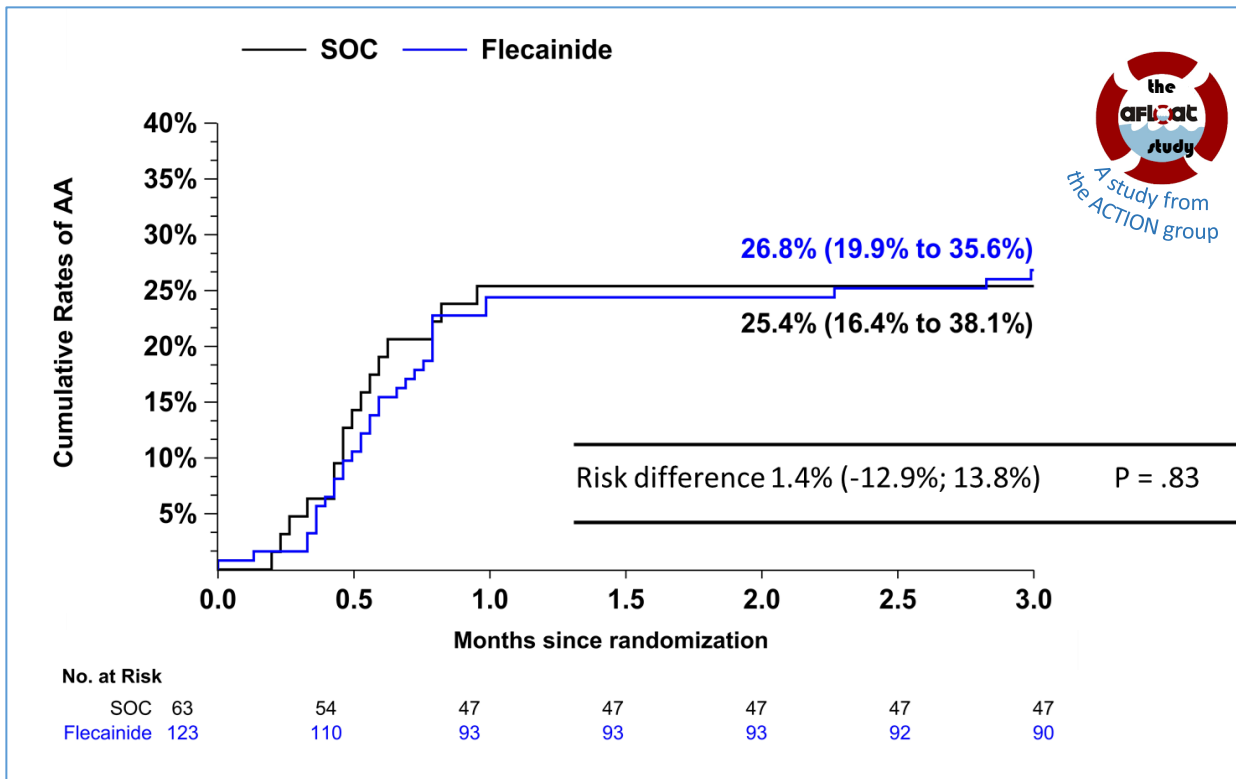
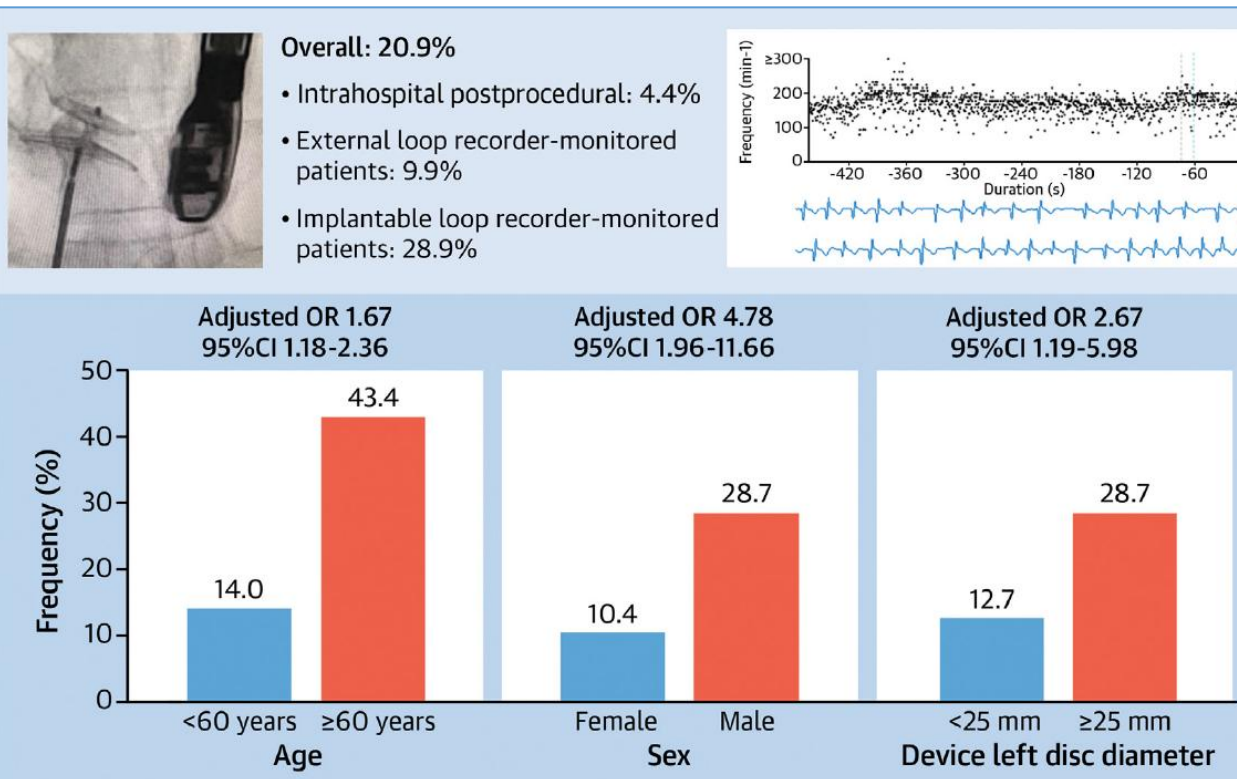
Paul Guedeney, MD,^a Mikael Laredo, MD,^a Michel Zeitouni, MD, PhD,^a Marie Hauguel-Moreau, MD,^b Thomas Wallet, MD,^a Benjamin Elegamandji, MD,^a Sonia Alamowitch, MD, PhD,^c Sophie Crozier, MD,^c Candice Sabben, MD,^d Sandrine Deltour, MD, PhD,^e Michaël Obadia, MD,^d Nadia Benyounes, MD,^f Jean-Philippe Collet, MD, PhD,^a Stéphanie Rouanet, MS,^g Nadjib Hammoudi, MD, PhD,^a Johanne Silvain, MD, PhD,^a Gilles Montalescot, MD, PhD^a

ORIGINAL RESEARCH ARTICLE

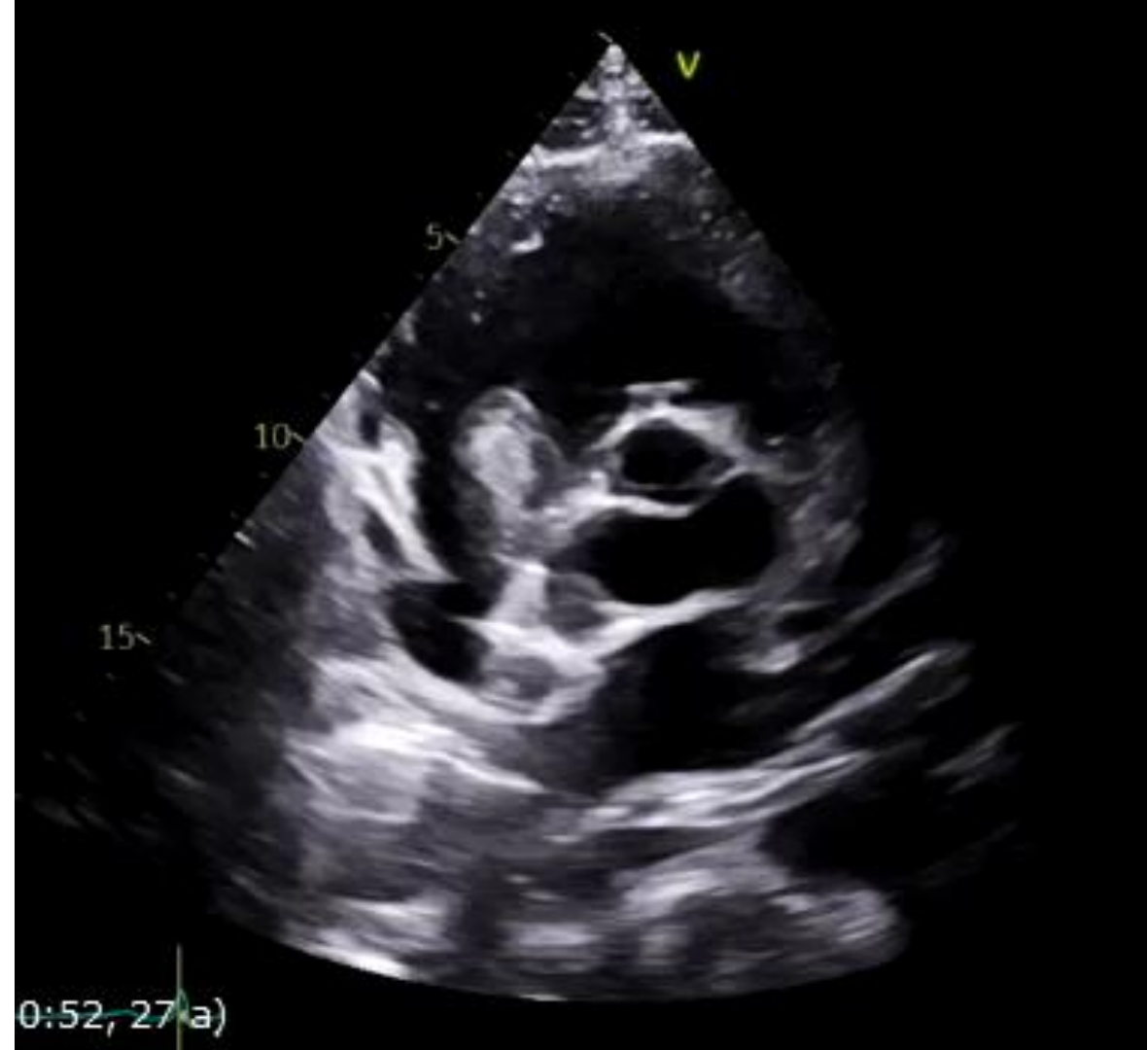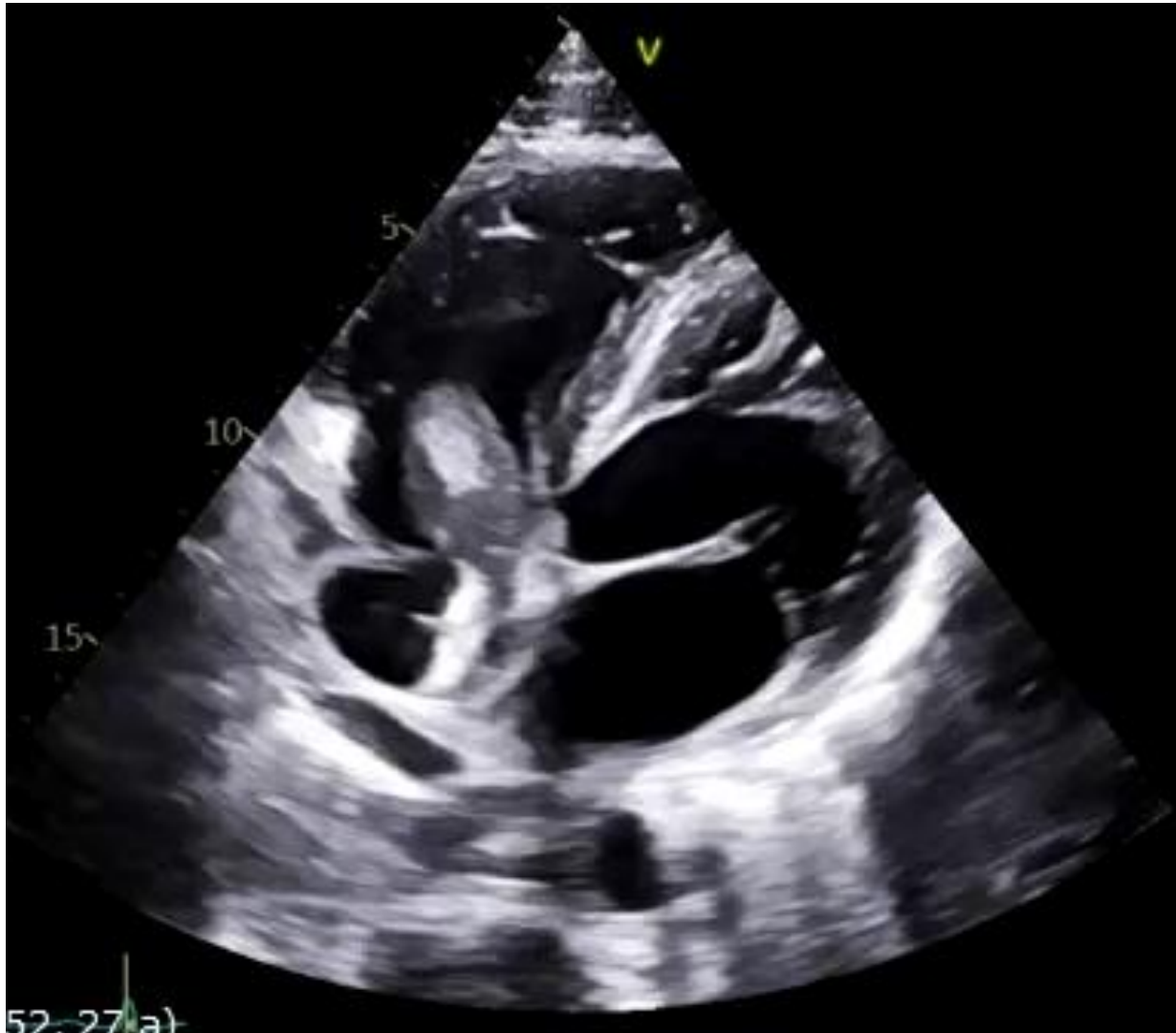Flecainide to Prevent Atrial Arrhythmia After Patent Foramen Ovale Closure: AFLOAT Study, A Randomized Clinical Trial

Editorial, see p 1669

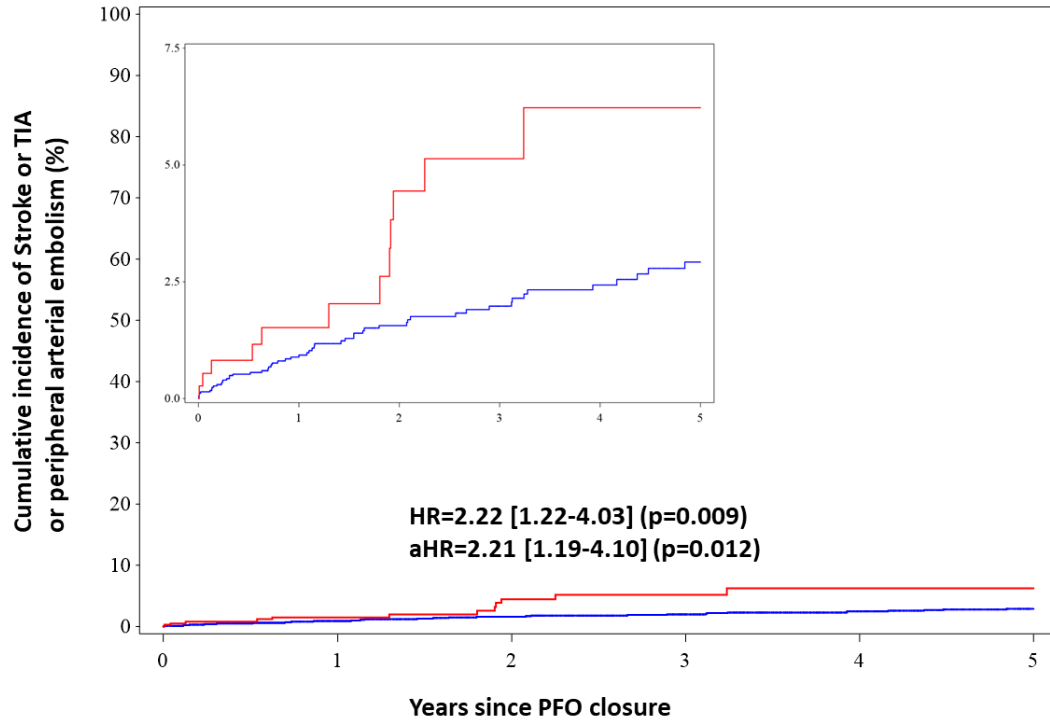
Marie Hauguel-Moreau, MD, PhD, Paul Guedeney, MD, PhD , Claire Dauphin, MD, PhD , Vincent Auffret, MD, PhD , Jean-Michel Clerc, MD, PhD, Eloi Marijon, MD, PhD , Meyer Elbaz, MD, PhD , Philippe Aldebert, MD, PhD, Farzin Beygui, MD, PhD, Wissam Abi Khalil, MD, PhD, Antoine Da Costa, MD, PhD, Jean-Christophe Macia, MD, PhD, Simon Elhadad, MD , Guillaume Cayla, MD, PhD , Xavier Iriart, MD , Mikael Laredo, MD, PhD , Thomas Rolland, MD , Yassine Temmar, MD, Maria Elisabeta Gheorghiu, MD , Delphine Brugier, PhD, Johanne Silvain, MD, PhD , Nadjib Hammoudi, MD, PhD , Guillaume Duthoit, MD , Abdourahmane Diallo, PhD , Eric Vicaut, MD, PhD, and Gilles Montalescot, MD, PhD for the ACTION Study Group



Risque infectieux



Risque des shunts résiduels



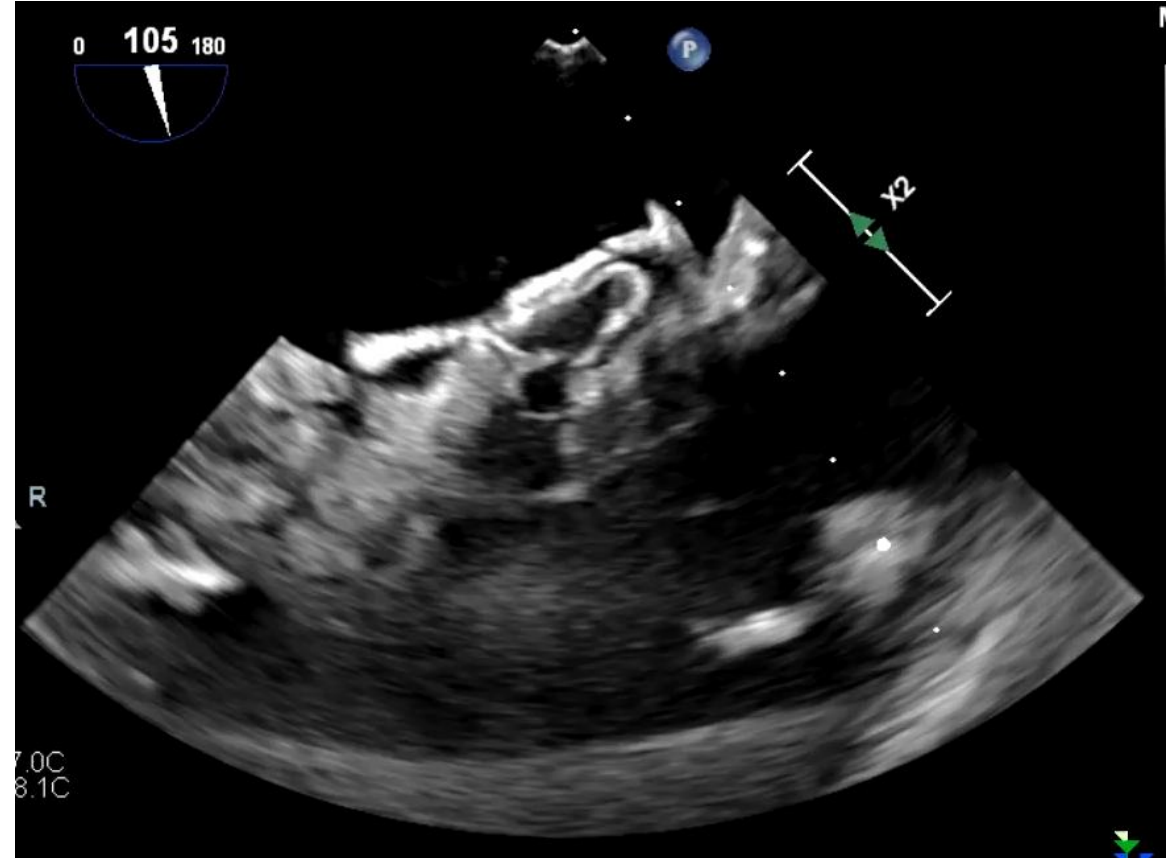
No. at risk

No significant RTL shunt

3552 2219 1615 1192 905 720

Significant RTL shunt

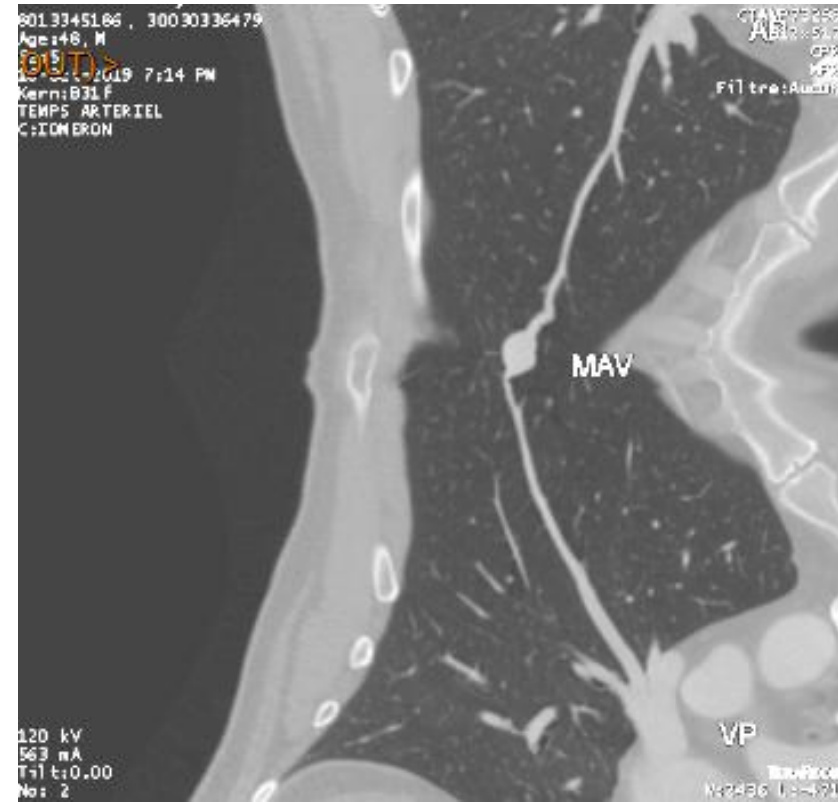
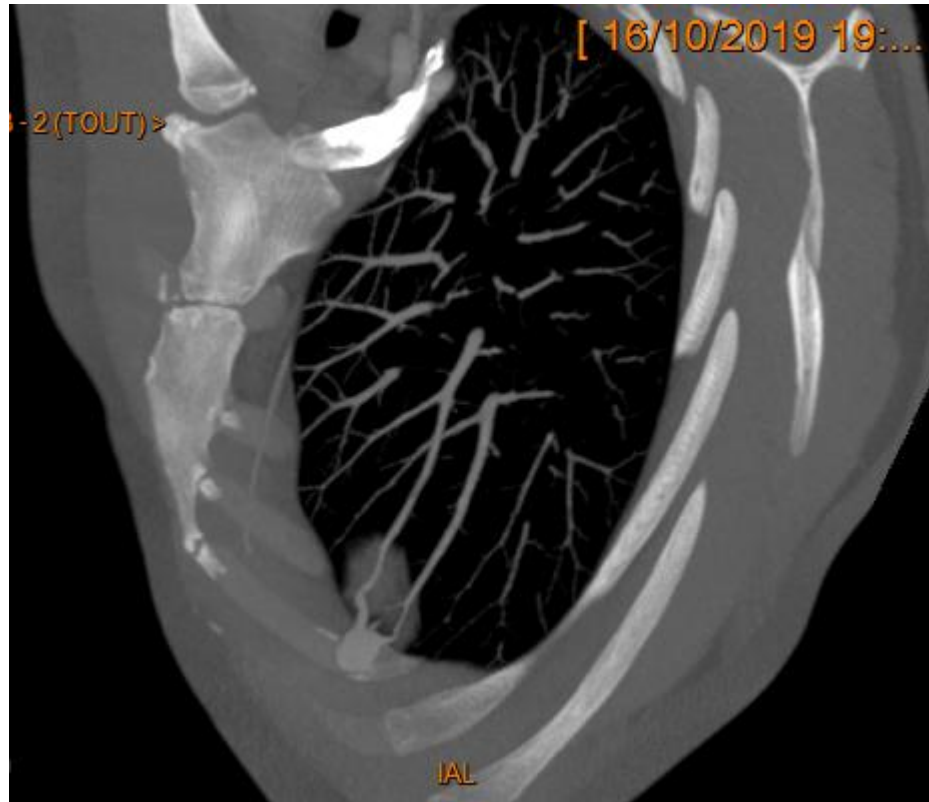380 243 150 101 55 37



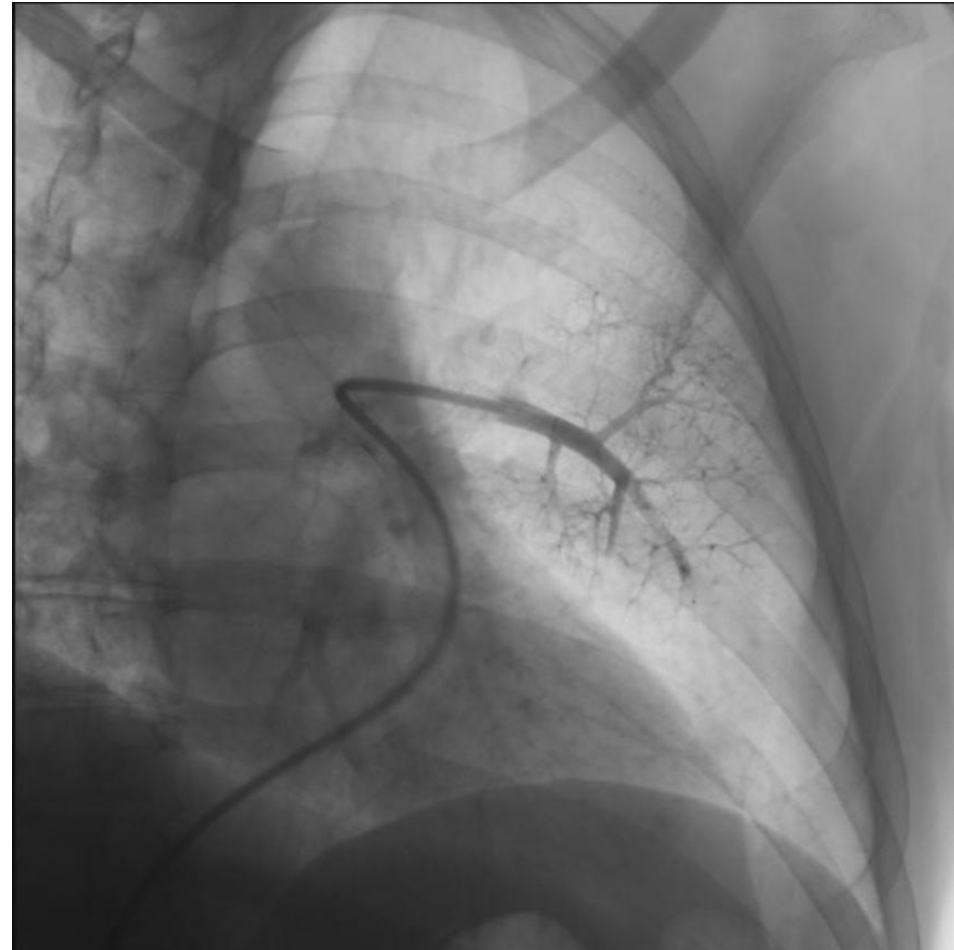
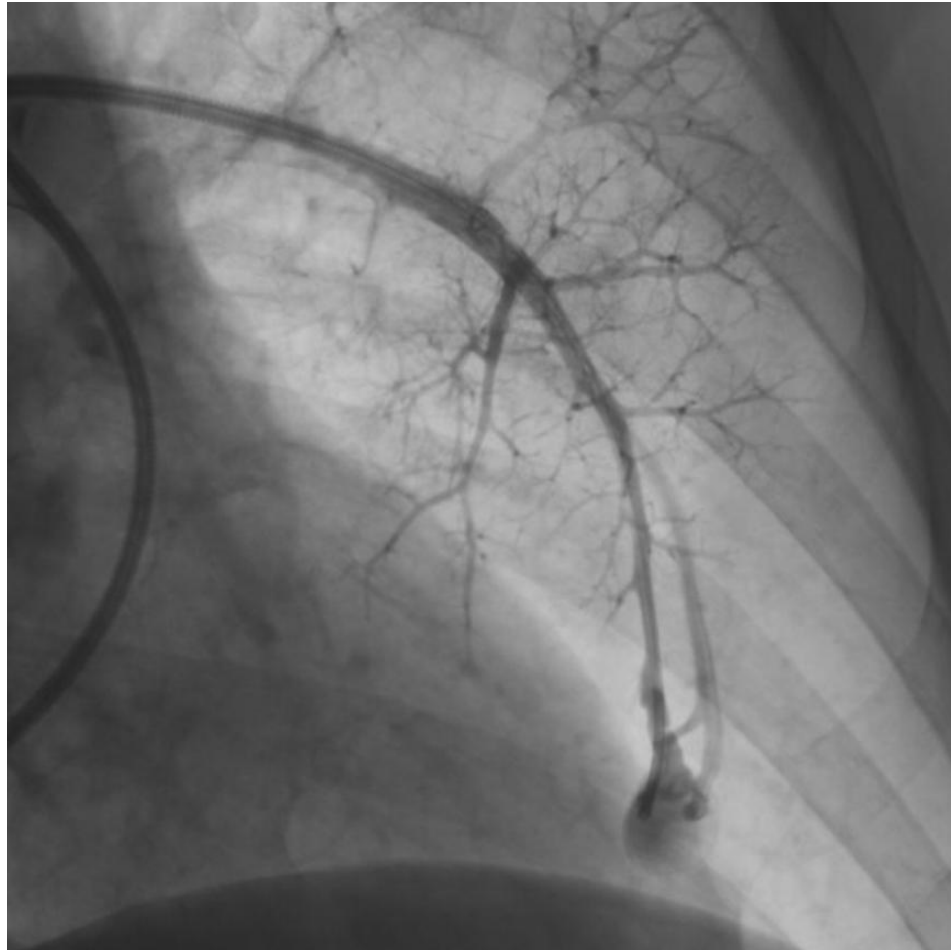FOP

Quid des shunts $D \rightarrow G$ sans FOP?

MAV pulmonaire



Fermeture de MAV pulmonaire



1. Penser et rechercher les FOP devant tout accident ischémique atypique
2. Rechercher les sources emboligènes
3. Fermer les FOP dans les indications classiques
4. Ne pas réfuter systématiquement les autres indications
5. La procédure doit rendre le septum étanche
6. Les cas complexes doivent être reconnus et nécessitent une vraie expertise
7. Après fermeture, les risques sont la FA (25%), le shunt résiduel (10%), l'endocardite (exceptionnelle).

